

**A LABORATORY MANUAL
FOR CEMENTUM AGE DETERMINATION
OF ALASKA BROWN BEAR
FIRST PREMOLAR TEETH**

by

Gary Matson, Larry Van Daele, Enid Goodwin,
Larry Aumiller, Harry Reynolds, Hank Hristienko.



- Gary Matson, Matson's Laboratory, Box 308, Milltown, MT 59851-0308
- Larry Van Daele, Alaska Dept Fish & Game, Wildlife Conservation, PO Box 1030, Dillingham, AK 99576
- Enid Goodwin, Alaska Dept Fish & Game, Wildlife Conservation, 333 Raspberry Road, Anchorage, AK 99518-1599
- Larry Aumiller, Alaska Dept Fish & Game, Wildlife Conservation, 333 Raspberry Road, Anchorage, AK 99518-1599
- Harry Reynolds, Alaska Dept Fish & Game, Wildlife Conservation, 1300 College Road, Fairbanks, AK 99701-1599
- Hank Hristienko, Manitoba Natural Resources, Wildlife Branch, Box 24, 1495 St. James Street, Winnipeg, MB, Canada R3H 0W9

Persons intending to cite this material should first contact the author(s) and/or the Alaska Department of Fish and Game. Because development of the methods described is ongoing, new information may be available. Due credit will be appreciated.

For ordering additional copies of this manual contact:

Matson's Laboratory
PO Box 308
Milltown, MT 59851-0308
(406) 258-6286

For further information contact:

Alaska Dept Fish and Game
Division Wildlife Conservation
333 Raspberry Road
Anchorage, AK 99518-1599
(907) 344-0541

The Alaska Department of Fish and Game conducts all programs and activities free from discrimination on the basis of race, color, national origin, age, marital status, pregnancy, parenthood, or disability. For information on alternative formats for this and other department publications, please contact the department ADA Coordinator at (voice) 907-465-4120, (TDD) 1-800-478-3648, or FAX 907-586-6595. Any person who believes she/he has been discriminated against should write to ADF&G, PO Box 25526, Juneau, AK 99802-5526 or O.E.O., U.S. Department of the Interior, Washington, DC 20240.

Cover artwork • Laura Friis

Typesetting/Formatting • Creative Image-Secretarial Shoppe



CONTENTS

| | |
|--|----|
| Introduction | 1 |
| Definitions/Terminology | 2 |
| Histology of tooth sections | 2 |
| Plate I. Slide 67. | 4 |
| Standardized method for cementum aging | 6 |
| Sources of error in cementum age determination | 6 |
| Assignment of the reliability index to cementum ages | 10 |
| A case study of cementum aging error: Skulseal 9103484 | 12 |
| Birth date and age reporting standardization | 12 |
| Tooth type standardization (Plate VII) | 12 |
| Using the manual for self testing (Plates VIII, IX, X, XI) | 13 |
| Introduction to the figure plates | 14 |
| Plate II. Season of annulus formation | 16 |
| Plate III. Season of annulus formation (continued) | 18 |
| Plate IV. Cementum aging error sources | 20 |
| Plate V. Cementum aging error sources (continued) | 22 |
| Plate VI. Assigning the reliability index | 24 |
| Plate VII. Cementum annuli in different tooth types | 26 |
| Plate VIII. Typical age classes | 28 |
| Plate IX. Typical age classes (continued) | 30 |
| Plate X. Examples for practice | 32 |
| Plate XI. Examples for practice (continued) | 34 |
| Testing cementum ages | 36 |
| Defining cementum aging accuracy | 36 |

| | |
|--|----|
| The "backup tooth" | 36 |
| Determining reproductive history from tooth sections | 36 |
| Acknowledgments | 37 |
| Literature cited | 37 |
| Appendix A - Selection and extraction of bear teeth | 40 |
| Appendix B - Sectioning and staining techniques for PM1 teeth | 43 |
| Lab safety and hazardous waste | 46 |
| Appendix C - ADFG cementum aging evaluation: Methods and results | 47 |

INTRODUCTION

The Alaska Department of Fish and Game (ADFG) has collected age data from virtually all brown/grizzly bears (*Ursus arctos*) harvested in the state since 1969. These data, in conjunction with information on sex and skull size, have been used to evaluate harvest levels and population trends.

ADFG biologists Lee Miller and Lee Glenn modified cementum aging techniques and applied them for use on brown bears in Alaska. Researchers in other areas have also modified cementum aging techniques for various mammalian species and at least one private laboratory (Matson's Laboratory, Milltown, Montana) provides cementum aging for clients around the world.

Brown/grizzly bear age data derived from cementum aging have been questioned since the inception of the technique. In 1988, ADFG set out to evaluate the accuracy and precision of their aging techniques by comparing the results of various individual tooth agers using different methods. A test sample was assembled that included 75 tooth sections prepared from known age brown bear PM1 teeth, and 25 from assigned age teeth. ADFG biologist Larry Van Daele designed the evaluation and served as coordinator. Three Department personnel participated in the evaluation: Enid Goodwin, Harry Reynolds, and Larry Aumiller. The fourth participant was Gary Matson, owner of Matson's Laboratory. Participants' experience with cementum aging varied from 1 to 20+ years.

Each participant aged each tooth section 3 times, then cementum ages were compared with known ages. All participants had errors in some cementum ages, but precision was considered to be satisfactory (Appendix C). Similar conclusions were reached by McLaughlin, et al. (1990) in their evaluation of Maine black bear cementum aging. In the ADFG evaluation, however, there was a significant difference in the accuracy of individual agers. This suggested that agers were using different cementum aging models.

A goal of the Department's evaluation project was to develop an instructional laboratory manual that would facilitate repeatability of both laboratory and cementum aging methods. Laboratories had passed along expertise by word of mouth from one technician to the next, but oral explanations can be both incomplete and misunderstood.

The literature contains descriptions of some tooth section characteristics of bears (Mundy and Fuller 1964, Marks and Erickson 1966, Stoneberg and Jonkel 1966, Sauer et al. 1966, Craighead et al. 1970, Rausch 1969, Willey 1974, Pearson 1975). However, no author gives standardized criteria for tooth section interpretation that would allow technicians to consistently interpret the same histological characteristics in the same way. This laboratory manual does that for the first time. The complete description/illustration of aging method can be called the Cementum Aging Model for brown bears. It provides for consistent determination of cementum ages by:

1. Describing characteristics of the first premolar (PM1) tooth section in detail, including the most likely error sources.
2. Standardizing the criteria for PM1 cementum aging.

3. Using photographs of known age tooth sections as training tools.
4. Describing the steps in tooth processing and section preparation that require standardization.

The aging methods described in this manual are applicable to black (*Ursus americanus*), grizzly and brown bears. The manual is designed to be used as a guideline only, and not as a complete, final reference. Variations in tooth section characteristics, even for the same species and tooth type, make necessary continued observation, testing, and refinement of the cementum aging model.

Discussions of tooth selection (for cementum aging) and extraction are in Appendix A. A general overview of laboratory techniques (chemical processing, sectioning, staining) are in Appendix B.

DEFINITIONS/TERMINOLOGY

Annulus = The annual dark cementum layer(s). The annulus may be simple, with a single component, or it may be complex, with more than one component. Annuli are also referred to in the literature as layers, rings, and bands. Minor components of the annulus have been called "false annuli". Major and minor components are defined by the criteria given on page 9.

Accuracy = Correctness.

Precision = Repeatability; consistency.

Dark cementum = The acellular cementum that is darkly stained in histological sections viewed with transmitted light. It appears to be primarily produced during winter in the northern hemisphere. Dark cementum is produced during other seasons, resulting in complex annual layers of light and dark cementum.

Note: There is no scientific evidence linking cyclic light and dark cementum production with any causative factor.

Light cementum = The abundant, cellular cementum that is lightly stained in histological sections viewed with transmitted light. It appears to be produced primarily during spring and summer in the northern hemisphere.

HISTOLOGY OF TOOTH SECTIONS

Tooth histology and the interpretation of structures used in cementum age determination have been reviewed in detail by Klevezal and Kleinenberg (1969) and by Johnston, et al. (1987).

The typical first premolar mid-sagittal section

Eruption of permanent premolar teeth occurs before northern interior grizzly bears den at the age of 8 months (Pearson, 1975). It is assumed that the Alaska brown bear premolars erupt at a similar age. During eruption and the first summer and fall of life, light cementum is deposited at the outer surface of the tooth root. By the end of the first fall season, the first premolar (PM1) has only a thin layer of light cementum (no annulus is present). The first annulus is formed during the first winter. By spring, PM1 of the yearling brown bear has the light cementum of the previous summer/fall and a single annulus of the winter just past.

Identification of the first annulus is made possible by correct identification of the dentine-cementum junction (Fig. 1, Plate I). The junction is a border between the striated dentine and the "spongy" cementum. It may appear to be a thin, dark layer or a lightly stained, amorphous zone (without histological organization as a specific structure).

Both dentine and cementum are formed throughout life. Dentine production by cells lining the pulp cavity gradually decreases the size of the cavity. Cementum production by cells on the outer surface of the root gradually increases the diameter of the root.

The periodontal membrane is an important indicator that all cementum is present at the point where it is observed. Cementum is sometimes removed by improper tooth extraction and lab processing.

A thin annual layer of light cementum has been correlated with successful cub rearing in some female black bears (Carrel 1992, Coy and Garshelis 1992). It is not known if the same thin layers can be reliably identified in the cementum of female brown bears, but the possibility suggests that gender should be included as essential data considered at the time of tooth section aging. The ager should examine all parts of the section for the characteristic thin layers, and record observations for further evaluation.

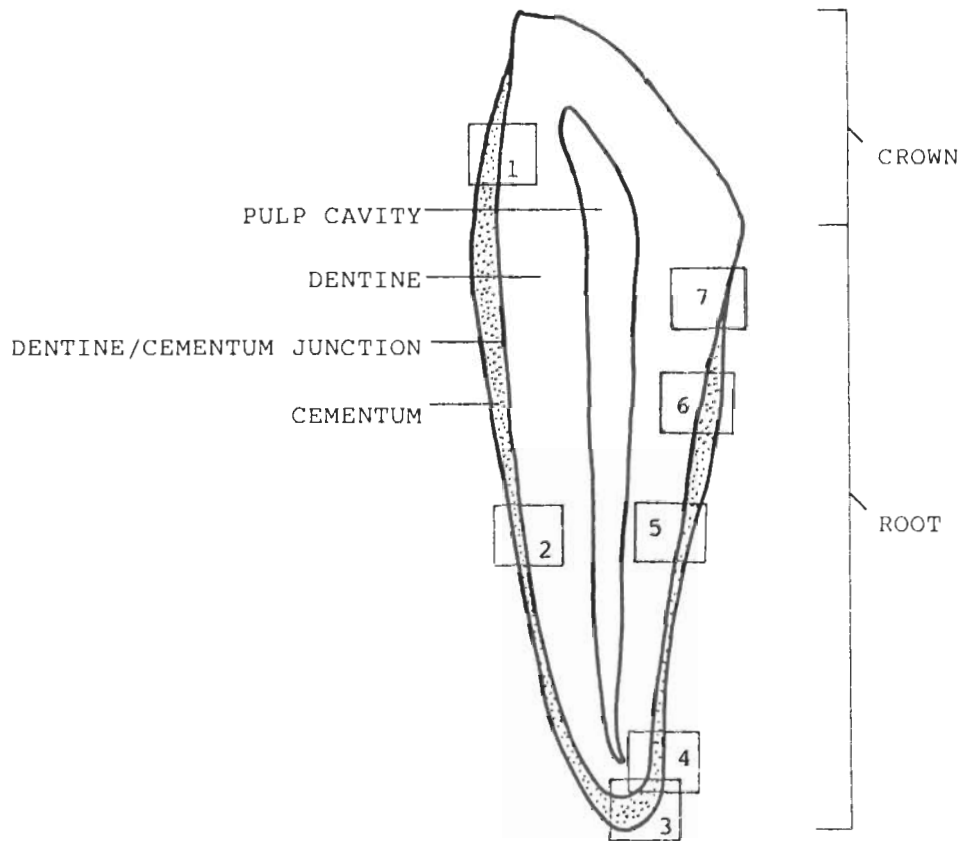


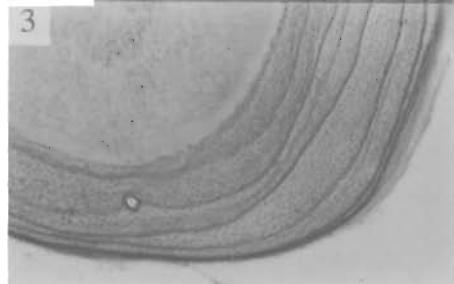

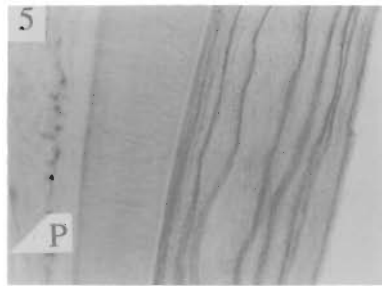
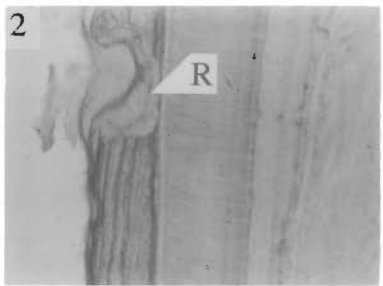
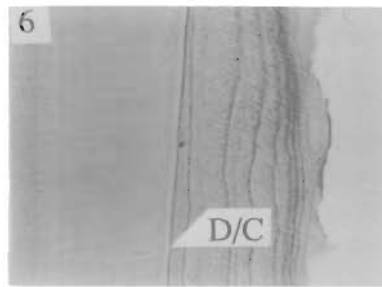

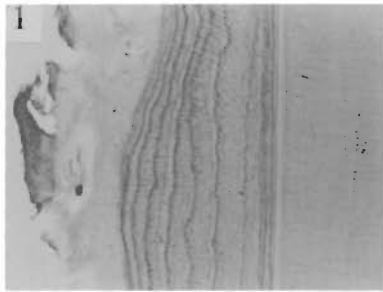
Fig. 1. Diagram of the typical mid-sagittal PM1 tooth section. Numbered rectangles represent areas that appear in the photographs of Plate I. The worn surface on the crown is posterior.

PLATE I. SLIDE 67.

Female. Tooth collected September, 1985. Known age 3.8 years. 40X. The photographs were taken in areas of the tooth section that correspond with the numbered rectangles of Fig. 1.

D = dentine, **LC** = light-staining cementum, **D/C** = dentine-cementum junction, **A** = dark-staining cementum annulus, **P** = pulp cavity, **PM** = periodontal membrane, **R** = area of resorption.

PLATE I.



STANDARDIZED METHOD FOR THE CEMENTUM AGING OF LONGITUDINAL SECTIONS OF UPPER AND LOWER PREMOLARS NUMBER 1 AND NUMBER 3

1. Refer to the tooth collection date. The last-formed annulus from spring-collected teeth will be so close to the outer surface of the root that it may not be clearly seen without the most careful observation.
2. Scan the entire section at low magnification for the points where the annuli are most distinct.
3. Count the annuli of at least 2 points of the same section, and of at least 2 sections.
 - a. Examine the dentine-cementum junction with special attention to the possible variations in the 1-year growth layer, often closely associated with the junction. Study the junction closely at all points in the section.
 - b. The count will often have to be made while moving the section, because the early (proximal) and late (distal) annuli are often clearly visible at different points of the section. In other words, a single point in the section may not clearly show cementum layers of both early and later years.
4. Resolve differences in the count by re-examination, with special attention to the criteria for the 1-year layer and for complex layer groups (see pages 20-23; Plates IV, V).
5. Finally, study all points of the section for evidence that does not support the determined age. If such evidence is found, begin again with the age determination of the section.
6. Assign a reliability index to the determined age (see page 10 and page 24; Plate VI).

SOURCES OF ERROR IN CEMENTUM AGE DETERMINATION: THE FIRST-FORMED ANNULUS, TEETH OF YOUNG BEARS, COMPLEX ANNULI, SPRING SEASON OF TOOTH COLLECTION, RESORPTION, INDISTINCT ANNULI

The five primary error sources in ~~cementum age determination of brown bear~~ PM1 tooth sections are:

1. Last-formed annulus ~~misinterpretation in spring-collected teeth~~.
2. Variable distance of the 1-year annulus from the dentine-cementum junction.
3. Complex annuli.
4. Portions of the tooth abnormal or missing.

5. Indistinct annuli.

Cementum aging error can be minimized by describing the error sources in detail, and establishing specific criteria that enable the ager to identify them during the age determination process. Criteria for identifying the five error sources follow.

Error source 1. Last-formed annulus misinterpretation in spring-collected teeth. (Plates II, III)

This potential error source is very important, and is shown in detail in Figs. 2-13. Known age tooth sections collected in the late spring (May, June) clearly show the last-formed dark annulus just visible near the extreme outer surface of the root. Teeth collected during the fall season have a thicker layer of peripheral light cementum that makes the last-formed annulus more identifiable.

There are two important reasons why the last-formed annulus of spring-collected teeth may be missed:

1. Light cementum deposition begins later and/or occurs more slowly in some individual bears. As a result, no identifiable layer may be present at the tooth section periphery. The absence of peripheral light cementum may prevent clear visualization of the last-formed annulus, even when the time of collection would clearly indicate that it should be present.
2. Peripheral cementum, including the last-formed annulus, is removed by tooth extraction or cleaning procedures. Three agents of cementum removal that should be avoided are:
 - a. Prolonged boiling in water to soften tooth attachments for extraction.
 - b. Chemical agents, such as bleach, that are used for cleaning.
 - c. Scraping of the tooth surface with any hard, sharp object; prying against the tooth root with an extracting tool.

The PERIODONTAL MEMBRANE is an important structure for confirming that all cementum is present on a tooth section. When the membrane is present, the extreme periphery of the tooth section can be seen with clear microscopic detail. BECAUSE OF THE CLOSENESS OF THE LAST-FORMED ANNULUS TO THE PERIPHERY OF THE TOOTH SECTION, THE INTACT PERIODONTAL MEMBRANE IS IMPORTANT FOR ACCURATE AGING OF THE SPRING-COLLECTED TOOTH. All of the three agents that cause damage to the periphery of the tooth should be avoided to maximize cementum aging accuracy, particularly of spring-collected teeth.

Error source 2. Variable distance of the 1-year annulus from the dentine-cementum junction. (Plate IV)

The first light cementum layer, just distal to the dentine-cementum junction, varies in thickness in the teeth of different bears. Consequently, the distance from the junction to the first annulus varies. If the criteria for identification of the 1-year annulus do not account for the three common variations, error may occur. For example, if the criterion for the first annulus is "the annulus that extends completely around the root tip" then under-aging error will occur by not counting the two other types of first annulus, described below.

The 1-year dark cementum growth layer may be in one of three locations.

1. Close to the dentine-cementum junction with no distinct separation from the junction (Fig. 17).
2. Separated from the junction but only at some points of the section; not continuous around the root tip (Fig. 16).
3. Broadly separated from the junction; continuous around the root tip (Figs. 14, 15).

The first annulus is clearly identifiable in 2. and 3. However, 1. requires that additional study be focused on the dentine cementum junction to identify the annulus.

- a). When the 1-year annulus and the junction are in close proximity, the combination of the two may give an appearance of a greatly thickened dark layer that is characteristically more prominent than is the junction alone (Fig. 17). If visual evidence confirms such thickened points, then identify the 1 year annulus as being in optical combination with the junction.
- b). If there are no thickened points, consider the location of the first visible annulus that is clearly separated from the junction. Use judgement and experience to determine whether the annulus indicates the age of 1 year or 2 years.

The annulus most probably indicates 1 year when it is not continuous around the root tip, or is located close to the dentine at the root tip.

The annulus most probably indicates 2 years when it is broadly spaced from the dentine at the root tip and continuous from one side to the other.

Caution: Plane of section can influence position of 1-year annulus.

The cementum annulus occurs in the tooth root as a cylinder with a domed cap at the root tip. This structure is built up in concentric layers as the tooth ages. Whenever the tooth section is taken far off the midline, different portions of each annulus are intersected at different angles, distorting the relationship to the dentine-cementum junction. For example, a 1-year annulus that is located close to the dentine and is not present at the extreme root tip may appear to be broadly spaced from the dentine and continuous around the tip when the section is taken far off midline. During the age determination process, the tooth section must be examined to confirm that it is near the midline before judgements are applied to the relative location of annuli and other tooth structures.

Error source 3. Complex annuli (Plates IV, V)

Complex annuli have one or more broad, darkly stained major components and one, or several, less prominent minor components. The minor components have been called "false annuli".

Incorrect identification of minor components of complex annuli (Figs. 13, 24) is an important potential error source. If minor components are incorrectly identified as annuli, then large over-aging errors can occur. On the other hand, large under-aging errors can result when major and minor components are incorrectly grouped together (Figs. 18-21). Identify minor components by two criteria:

1. They are either absent or weakly stained in parts of the section where major annual components remain prominent.
2. They are annually repeated, at any given point of the tooth section, with similar breadth, staining intensity, and separation from other components.

During the process of cementum analysis, it is helpful for the ager to recognize that light cementum layer thickness decreases with age. Each annual increment of light cementum is thinner than the year before, so that the separation between annuli gradually decreases. The first five or six light layers are the thickest. Thereafter, they may become so thin that annuli are not clearly separated from each other.

To accurately age the tooth section with complex annuli, it must be carefully examined at all points. Annulus recounts must continue with consistent application of the two criteria given above for minor annulus components. Repeatability of the annulus count indicates that the best estimate has been obtained. Counts by more than one ager with reconciliation of differences between agers improve aging precision.

Tooth sections of **young bears with complex annuli** are a special problem because the annulus is not present enough times to permit identification of the annually repeated pattern (Figs. 24, 25).

For the inexperienced ager, it is good practice to identify tooth sections of middle-aged bears (e.g. 4-8 years old) and to **use these sections as "models"** for both light cementum layer thickness and annulus characteristics. For example, a study of middle age tooth sections may clearly show that a light layer containing "false" annuli is far too thin to be as old as the false annuli would indicate.

Error source 4. Portions of the tooth abnormal or missing. (Plate V)

A frequent cause of abnormal cementum is resorption. It is a physiological process by which cementum is removed from the tooth. It also occurs in bone, and is thought to be a response to a transient high calcium demand (Myrick, 1988). Calcified tissue lost to resorption may be replaced later in life. Areas of resorption and replacement in the tooth section are easily identified microscopically (Figs. 22, 23).

Breakage often occurs during the somewhat difficult tooth extraction process, and can be minimized by following the suggestions in Appendix A. It is of value to have the entire tooth root for cementum aging, because the points that have the clearest arrangement of annuli vary among individuals and usually include the root tip itself. However, broken bear PM1 with missing root tips may provide good age analyses because the tooth typically has an area near the gumline where cementum is thickened and contains a distinct annulus arrangement (Figs. 1 (Page 5), 49).

Error source 5. Indistinct annuli (Plate VI)

Both biological and technical variation may cause indistinct annulus staining (Fig. 29). Annuli that are indistinctly stained may be missed during aging.

ASSIGNMENT OF THE RELIABILITY INDEX TO CEMENTUM AGES (PLATE VI)

The tooth section ager acknowledges varying degrees of confidence among results by assigning each a reliability index. The index is a subjective judgement of accuracy.

Consequences of error are greater for younger ages, so the precision requirement for the highest reliability rating is similarly greater.

Any time the ager determines that a result may not be exact, the range of possible results should be given. For example, each of the results 9A (9-10), 7B (6-7), and 5C (3-5) is accompanied by a specified range of possible ages. The user of the age data can determine which ends of the ranges will most correctly apply for each use.

The age reported as the primary result should be the one supported by the strongest evidence, and not the one that is in the middle of the possible range. For example, the result 17A (16-19) means the ager observed stronger evidence for the age of 17 years, than for 16 or 19 years.

| RELIABILITY INDEX | | | |
|-------------------|-------------|-------|--------|
| Determined Age | A | B | C |
| 1-8 years | +/- 0 years | +/- 1 | +/- 2 |
| 9-15 | +/- 1 | +/- 2 | +/- 3 |
| 16+ | +/- 2 | +/- 3 | +/- 4+ |

Criteria for assignment of the index in bear tooth sections:

"A" - Nearly certain to be correct, within the stated limits, because the annuli are clearly defined and potential error sources are absent. Additionally:

1. The presence of periodontal membrane confirms that all the cementum is present in the section.
2. In spring-collected teeth, the last-formed annulus is clearly visible at the section periphery.

"B" - Less certain to be correct. One or more error sources are present:

1. The 1-year annulus is not clearly defined within the limits of the criteria stated above.
2. The tooth section is from a young bear and it cannot be determined with certainty whether annuli are complex (multiple components) or simple (single component) because too few are present to permit identification of the repeated annual pattern.
3. Complex annuli of the older bear tooth **cannot be clearly separated** into major and minor components.
4. The spring-collected tooth lacks a clearly identifiable last-formed annulus near the extreme periphery of the section because:
 - a. The ~~periodontal~~ membrane is absent.
 - b. The ~~membrane~~ is present, but no clearly visible peripheral annulus is present.
5. Major portions of the tooth root or its cementum are missing, because of breakage or resorption, and there is no portion available for study that clearly shows annuli.
6. The annuli are not clearly visible because they are ~~indistinctly~~ stained.

"C" - Result is uncertain. Error sources are as given for "B" reliability.

A CASE STUDY OF CEMENTUM AGING ERROR: SKULSEAL 9103484 (PLATE VI, FIG. 27)

A tooth from a presumed yearling brown bear (date of kill 7 May) was sent to Matson's Laboratory for cementum aging. Matson determined the age as 2 years, with a reliability of "A". Subsequently, it was determined that the skull and canine tooth characteristics were of such high reliability that the animal could be regarded as a known age yearling. Matson's cementum age of 2 years was determined on the basis of the large amount of light cementum present at the periphery of the tooth (Plate VI, Fig. 27). The light cementum layer was so thick that it was mistakenly judged to be the annual thickness. In fact, the thick light layer had to have been produced during the short period in spring before the 7 May date on which the bear was killed. Variations in light cementum layer thickness have been observed among teeth from different individuals of the same age, extracted at the same time. Layer thickness variation also occurs from one point to another on the same tooth, and may also occur when the sectioning plane is off-midline because of technical variation or tooth curvature.

The study of the known age tooth sections in the Alaska Department of Fish and Game's reference collection showed that the thick layer of peripheral light cementum in Skulseal 9103484 was unusual for a tooth collected in early May. A second factor contributing to the error was the absence of periodontal membrane, which prevented the certain identification of the extreme section periphery. However, a tooth section with similar characteristics could certainly be expected to occur again. Therefore, the criterion for assignment of the "A" reliability index was changed. The changed criterion requires that the last-formed peripheral dark annulus be clearly visible in spring-collected PM1 sections before reliability "A" is assigned. Otherwise, the reliability "B" is given (see above).

This case study illustrates how the cementum aging model must be refined as experience dictates. Note that Skulseal 9103484 might be aged in the same way again, but not with an "A" reliability if criteria are correctly applied.

BIRTH DATE AND AGE REPORTING STANDARDIZATION

The Alaska Department of Fish and Game assumes a birth date of 1 February for the brown bear. Cementum ages are reported with a fractional year added to account for the age that occurred between the annual "birthday" and the date of kill (or tooth extraction from the live bear). The advantage of adding a fraction of age to that of the last full year is immediate association between the age and the season of tooth extraction (for example, immediate indication of whether the bear was from spring or fall harvest).

TOOTH TYPE STANDARDIZATION (PLATE VII)

Annuli have been described in a variety of tooth types of brown, black and grizzly bears (Mundy and Fuller 1964, Marks and Erickson 1966, Stoneberg and Jonkel 1966, Rausch 1969, Sauer et

al. 1966, Craighead et al. 1970, Willey 1974). Pearson (1975) noted that the location of the first annulus with respect to the dentine-cementum junction was variable not only among individuals but also among different tooth types from the same individual.

The upper first premolar tooth has been selected for the standardized tooth for four reasons: 1) Its small size makes it convenient for processing; 2) It can be extracted from live bears; 3) Its physical shape permits better tooth sections: It is less curved and less pointed at its tip than the lower first premolar (Kerr 1992); 4) It erupts early in life, and an annulus will be present representing the first winter. It is desirable to use only this single tooth type for cementum aging in order to minimize the variation in annuli characteristics. See Appendix A for a diagram that identifies the premolar teeth in the bear.

The authors studied differences among tooth types of the same individual for a small number of brown bears. An identifiable first (1-year) annulus was observed in each of the tooth types examined (Plate VII). This evidence indicates that different tooth types may be substituted for the standard PM1.

If UPM1 is not available, use substitute teeth in this order of preference: LPM1, UPM3, UPM4, LPM4.

USING THE MANUAL FOR SELF TESTING (PLATES VIII, IX, X, XI)

The plates have two typical regions from each of twelve tooth sections. Plates VIII and IX are illustrative of six different age classes. Plates X and XI are examples that may be somewhat more difficult to age.

Cover the written information on the left-hand page, opposite the photographs. After studying them, check the cementum ages you determined.

INTRODUCTION TO THE FIGURE PLATES

The photographs in all but Fig. 27, and the entire Plate VII were made from known age tooth sections in the Alaska Department of Fish and Game reference collection. These sections were stained with Hematoxylin. The photographs of Plate VII, and Plate VI, Fig. 27 were made from tooth sections processed at Matson's Laboratory and stained with Giemsa. The tooth collection date is given on each photograph.

The format for photograph captions is as follows:

FIG. 1. SLIDE 32. M. 10/77. KAT 4.8. 60X. 2MM ABOVE ROOT TIP, POSTERIOR.

Explanation of caption format:

Slide number = The slide number in the Alaska Department of Fish and Game reference collection. This is the collection that was used for the Department's cementum aging evaluation project.

M = male, **F** = female.

10/77 = Date of kill, or of tooth collection from the live animal.

KAT 4.8 = Known age tooth 4.8 years.

Anterior/Posterior = Anterior or posterior portions of the tooth section. These regions of the tooth section can be determined by the fact that the gumline on the anterior tooth surface is much closer to the crown tip than it is on the posterior surface. If not designated in the figure caption, then this orientation could not be determined.

PLATE II. SEASON OF ANNULUS FORMATION

TEETH EXTRACTED IN SPRING SEASON

- FIG. 2. SLIDE 15. M. 4/86. KAT 4.3. 140X. 1MM ABOVE TIP. POSTERIOR. Light cementum production had not yet resumed when the tooth was taken, and no dark annulus is visible at the extreme periphery of the section. The darkly stained zone at the section periphery is periodontal membrane. Three annuli are clearly visible, with the first being distinctly separated from the dentine/cementum junction by a light cementum layer.
- FIG. 3. SLIDE 15. 140X. 7MM ABOVE TIP, 2MM BELOW GUMLINE, SAME SIDE. No peripheral annulus is visible, although a zone of darkly staining cementum is present. Three annuli are clearly visible. The presence of periodontal membrane enhances the histological detail at the periphery of the cementum.
- FIG. 4. SLIDE 6. M. 5/85. KAT 4.4. 140X. 3MM ABOVE TIP, POSTERIOR. The first annulus is close to the dentine/cementum junction, and somewhat indistinct. There are three identifiable annuli; none is visible at the section periphery.
- FIG. 5. SLIDE 6. 140X. 7MM ABOVE TIP, 2MM BELOW CROWN. The first annulus is not distinctly separated from the dentine/cementum junction. The darkly stained cementum at the section periphery may represent a completely formed annulus, but light cementum production that would make the annulus visible had not yet begun when the tooth was taken.
- FIG. 6. SLIDE 51. F. 6/85. KAT 4.5. 140X. 5MM ABOVE TIP. A thin layer of light cementum is present at the section periphery, and the last-formed annulus is visible.
- FIG. 7. SLIDE 51. 140X. 7MM ABOVE TIP, 2MM BELOW CROWN.

PLATE II.


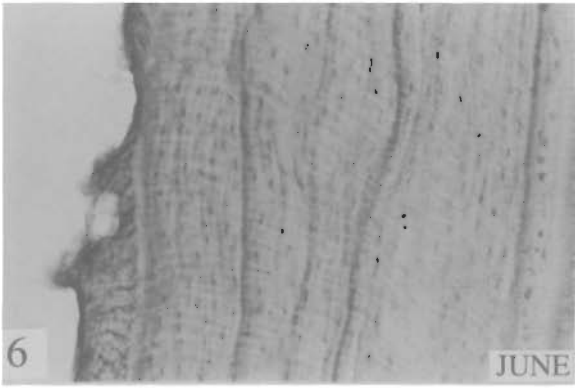
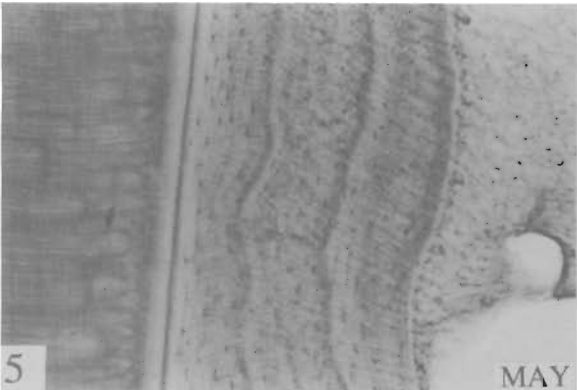

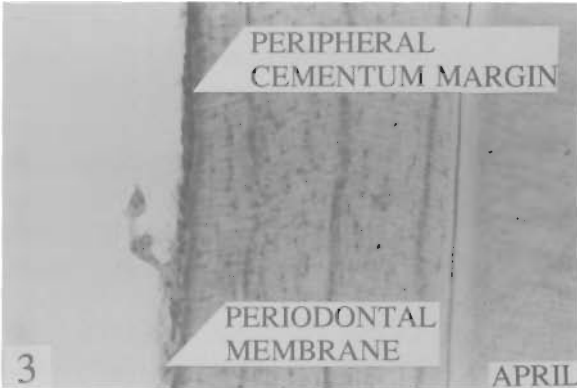
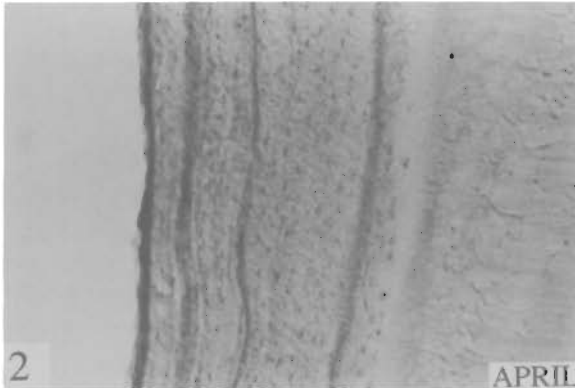


PLATE III. SEASON OF ANNULUS FORMATION (CONTINUED)**TEETH EXTRACTED IN FALL SEASON**

FIG. 8. SLIDE 64. F. 9/83. KAT 4.8. 140X. 3MM ABOVE ROOT TIP, POSTERIOR.

Teeth collected during the fall season have abundant **light cementum** at the tooth root periphery.

Apparent annuli at the periphery of fall-collected teeth are **minor components (AC)** of complex annuli, and are: 1) Narrower than major components and **less darkly stained**; 2) Not present at most parts of the tooth section; 3) Analogous to minor components of the annually repeated complex annuli **of previous** years.

FIG. 9. SLIDE 64. 140X. 6MM ABOVE ROOT TIP, 2MM BELOW GUMLINE, SAME SIDE.

FIG. 10. SLIDE 32. M. 10/77. KAT 4.8. 140X. 5MM ABOVE ROOT TIP.

FIG. 11. SLIDE 32. 140X. OPPOSITE SIDE, 6MM ABOVE TIP.

FIG. 12. SLIDE 3. M. 11/86. KAT 2.9. 140X. 1MM ABOVE ROOT TIP, POSTERIOR.

FIG. 13. SLIDE 3. 140X. 6MM ABOVE ROOT TIP, 2MM BELOW GUMLINE. SAME SIDE.
AC = Minor annulus component.

PLATE III.

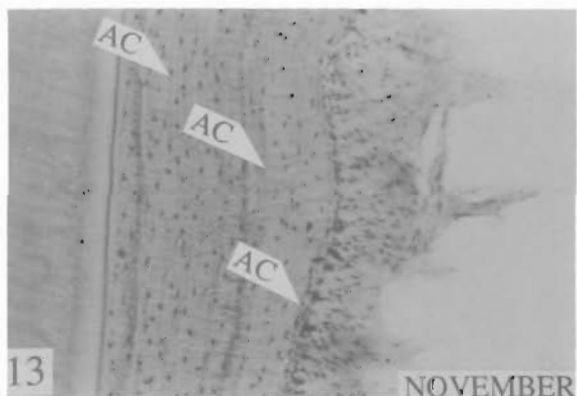
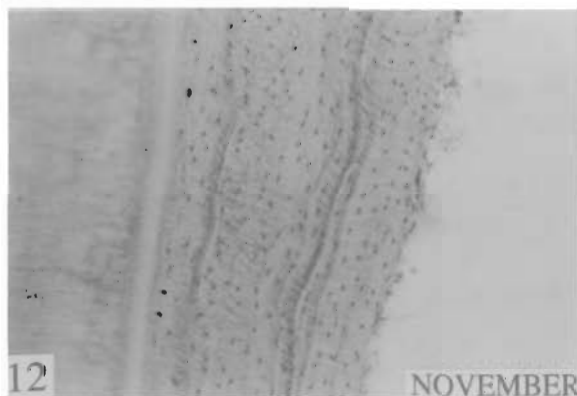
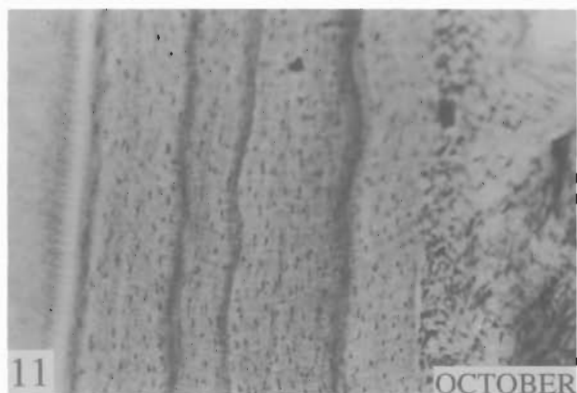

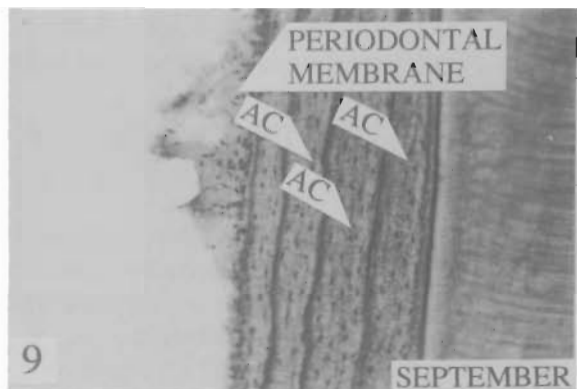
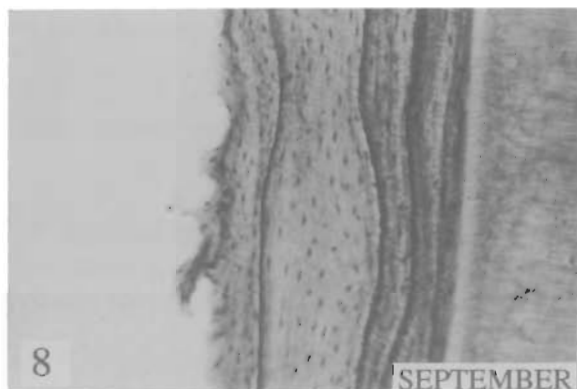


PLATE IV. CEMENTUM AGING ERROR SOURCES:

POSITION OF 1-YEAR ANNULUS COMPLEX ANNULI

FIG. 14. SLIDE 3. M. 11/86. KAT 2.9. 53X. 1MM ABOVE ROOT TIP. The 1-year annulus is clearly separated from the dentine by a broad layer of light cementum.

The variable position of the 1-year annulus is a potential error source in cementum aging.

There are three possible variations of the 1-year annulus (mid-sagittal section): 1) Broadly separated from the dentine, and continuous around the root tip. 2) Narrowly separated from the dentine, and not continuous around the root tip. 3) Not clearly separated from the dentine.

The 1-year annulus may exhibit variable separation in the same tooth section, and all points of the section should be examined for its identification.

FIG. 15. SLIDE 3. 140X. 7MM ABOVE TIP. OPPOSITE SIDE

FIG. 16. SLIDE 56. F. 9/84. KAT 6.8. 53X. 1MM ABOVE ROOT TIP. The 1-year annulus is close to the dentine.

FIG. 17. SLIDE 56. 140X. 6MM ABOVE TIP, 4MM BELOW GUMLINE. SAME SIDE. At this point of the section, the 1-year annulus appears only as a thickened dentine-cementum junction.

Some PM1 sections may have no point at which the 1-year annulus is clearly separated from the dentine.

FIG. 18. SLIDE 62. M. 6/85. KAT 12.5. 53X. 8MM ABOVE TIP, 2MM BELOW GUMLINE. At this point of the section there appear to be 7 complex annuli.

FIG. 19. SLIDE 62. 53X. ADJACENT. 7MM ABOVE TIP. At this point of the section, 12 (or more) complex annuli can be identified by grouping components.

Incorrect grouping of complex annulus components is an important cementum aging error source.

To minimize the error, the ager should identify the point(s) of the section at which the pattern of complex annuli is most regularly repeated. Then, the components should be grouped by applying the specific criteria described on page 9.

PLATE IV.

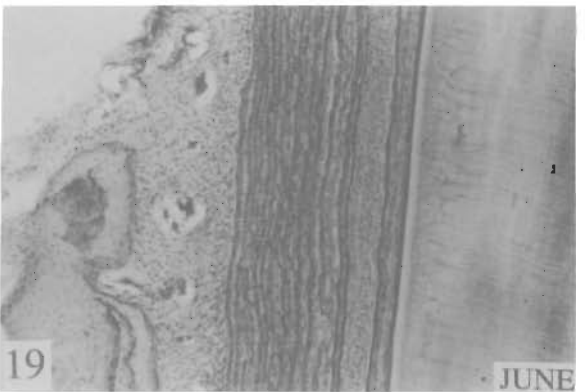
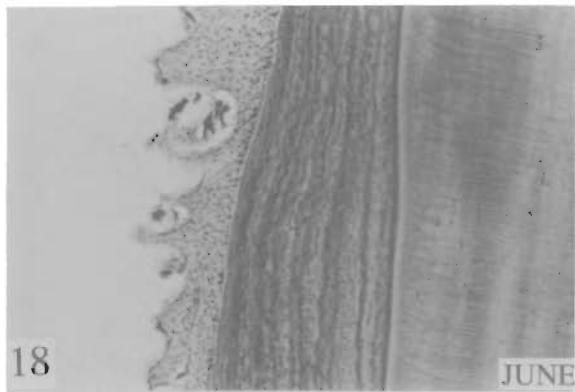
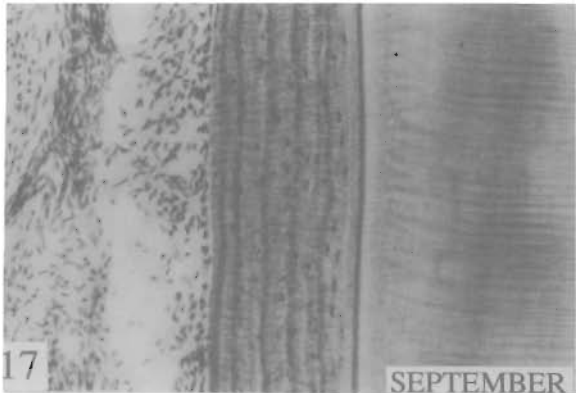
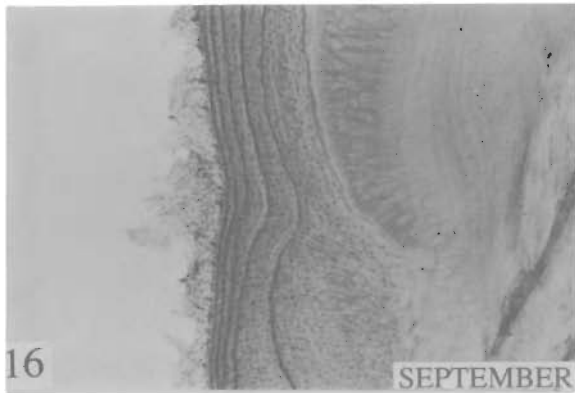
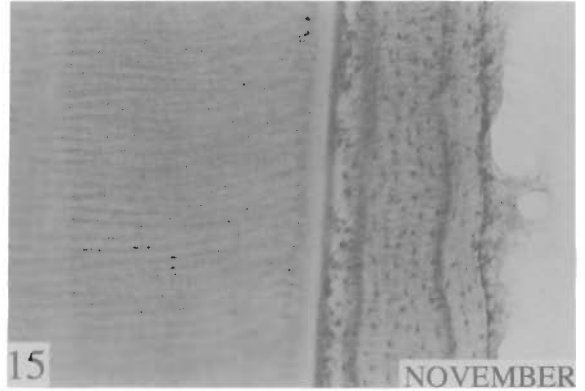
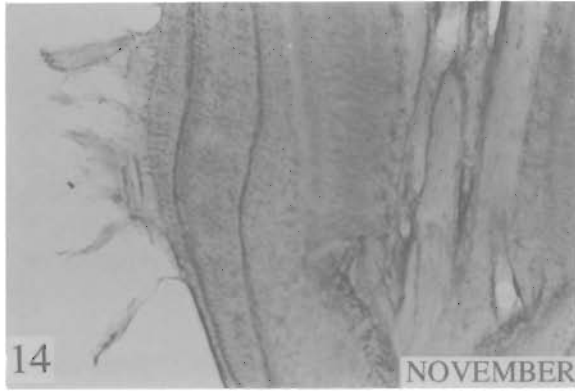


PLATE V. CEMENTUM AGING ERROR SOURCES (CONTINUED)**COMPLEX ANNULI; RESORPTION; TEETH OF YOUNG BEARS**

FIG. 20. SLIDE 63. F. 5/84. KAT 8.5. 140X. 2MM ABOVE TIP. There are 6 distinct annuli.

FIG. 21. SLIDE 63. 140X. OPPOSITE SIDE, 4MM ABOVE TIP. There are 8 distinct annuli.

During cementum aging, examine every point of the section. Only experience will develop the judgement that will enable the ager to identify the point(s) of the section at which the annulus pattern is regular and most likely to provide an accurate count. Note that the annulus pattern in Fig. 20 is irregular, having annuli present in a pattern that is not repeated. The pattern of Fig. 21 is uniformly repeated and more likely to permit an accurate count.

It is frequently necessary to use different points of the same tooth section for the most regular annulus pattern of different years. For example, a regular annulus pattern may be seen at one point for the early years of life and at a different point for the later years.

FIG. 22. SLIDE 67. F. 9/85. KAT 8.8. 140X. 5MM ABOVE TIP. ANTERIOR. Resorption may remove any amount of cementum from any point of the tooth

After resorption has taken place, the "healed" area will again display annuli, but with the resorbed years missing. Identify resorbed areas by their disrupted histological structure.

FIG. 23. SLIDE 67. 140X. 7MM ABOVE TIP, SAME SIDE. Minor areas of resorption may have produced the irregularities (I) in annuli of years 6 and 7.

FIG. 24. SLIDE 35. M. 10/71. KAT 2.8. 140X. 7MM ABOVE TIP, 2MM BELOW GUMLINE. POSTERIOR. Minor annulus components (AC) stain almost as darkly as major ones, creating a confusing pattern.

Complex annuli create a unique source of error in young bears, because the annuli are not repeated enough times for a pattern to be identified.

FIG. 25. SLIDE 35. 140X. ROOT TIP, SAME SIDE. Minor annulus components are present in a less confusing pattern at this point of the section.

PLATE V.

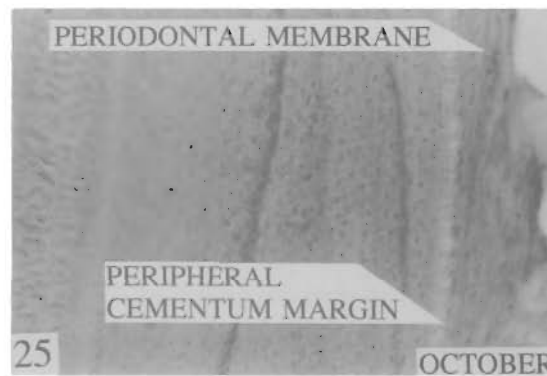
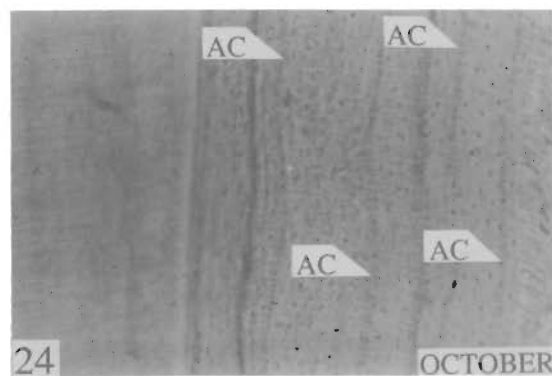
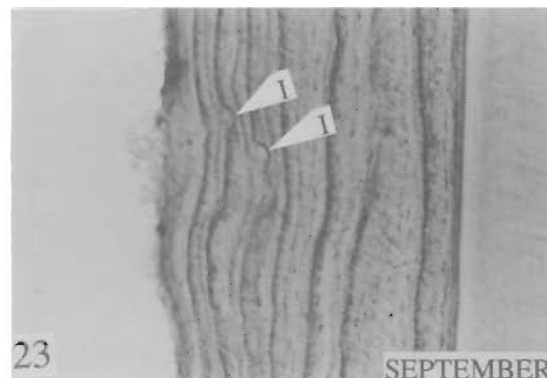
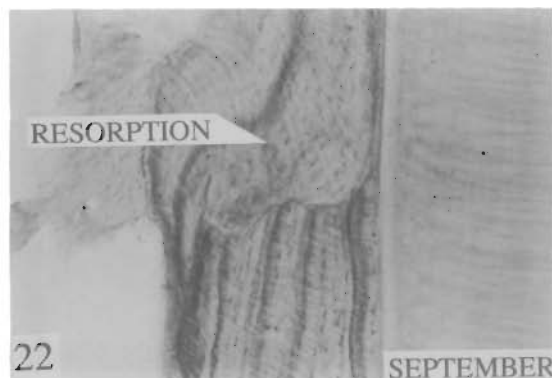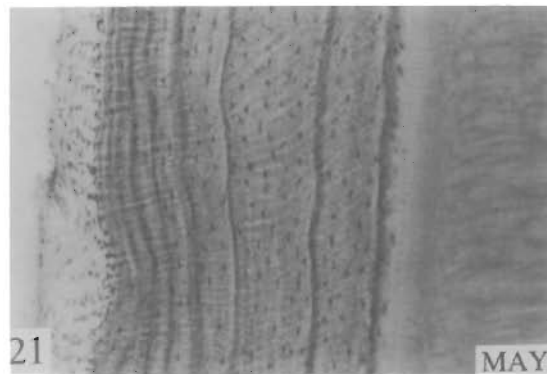
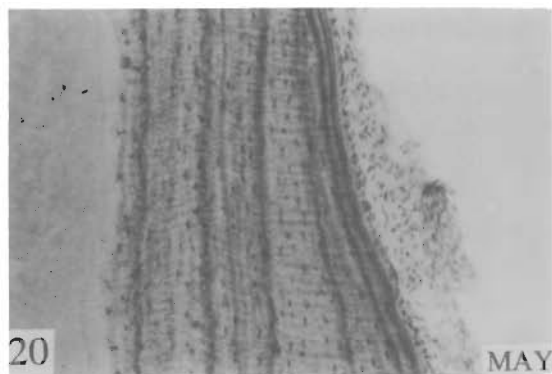


PLATE VI. ASSIGNING THE RELIABILITY INDEX

FIG. 26. SLIDE 6. M. 5/85. KAT 4.4. 140X. 6MM ABOVE ROOT TIP. POSTERIOR.

The regular annulus pattern, intact periodontal membrane, and good histological detail at the outer surface of the root permit the assignment of the "A" reliability index.

FIG. 27. SKULSEAL 9103484. M. 5/7/91. AGE DETERMINED FROM SKULL AND CANINE TOOTH CHARACTERISTICS TO BE 1 YEAR. 140X. 2MM BELOW GUMLINE. POSTERIOR.

It cannot be determined if cementum is missing because the periodontal membrane is absent. The "B" reliability index should be assigned.

Both periodontal membrane and cementum are removed by 1) prolonged boiling of skulls/mandibles to extract teeth, 2) bleaches and other chemical agents, 3) abrasive physical agents.

The tooth was removed by the Alaska Department of Fish and Game, and the section was prepared by Matson's Laboratory.

FIG. 28. SLIDE 69. F. 6/79. KAT 3.5. 140X. 2MM BELOW GUMLINE. POSTERIOR.

The regular annulus pattern and distinct peripheral dark annulus permit the "A" reliability index.

FIG. 29. SLIDE 45. M. 5/74. KAT 5.4. 140X. 8MM ABOVE TIP. INDISTINCT ANNULI.

The ager must estimate the possible range of annulus counts, and assign a reliability index that is consistent with that range.

FIG. 30. SLIDE 38. F. 7/71. KAT 2.6. 140X. 5MM BELOW GUMLINE. ANTERIOR.

This point of the tooth section clearly shows 3 annuli uniformly repeated. Other points of the section clearly show two annuli.

When different points of the same tooth section show annuli in a distinct and repeated pattern but give different counts, then determine the range of possible counts and assign a reliability index consistent with that range.

FIG. 31. SLIDE 32. M. 10/77. KAT 4.8. 140X. 2MM ABOVE ROOT TIP. ANTERIOR.

Annuli are simple and in a regular pattern. There is a clearly identifiable 1-year annulus. The periodontal membrane is intact, providing good histological detail at the outer surface of the root. All characteristics favor an accurate annulus count and the "A" reliability index can be assigned.

PLATE VI.

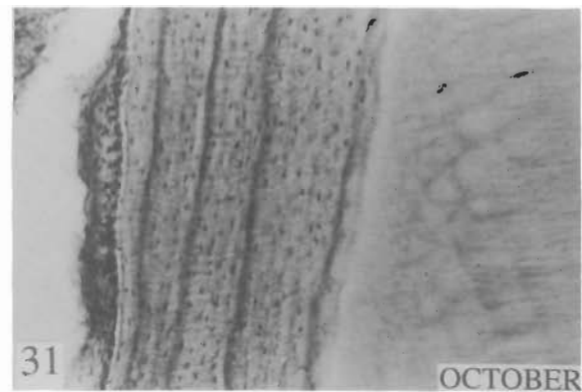
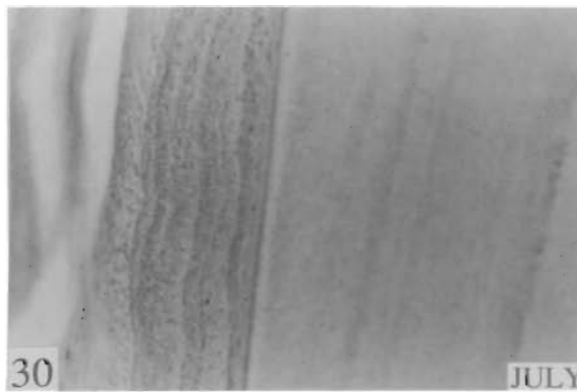

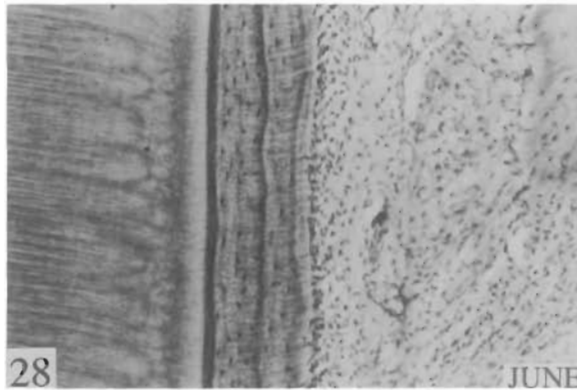

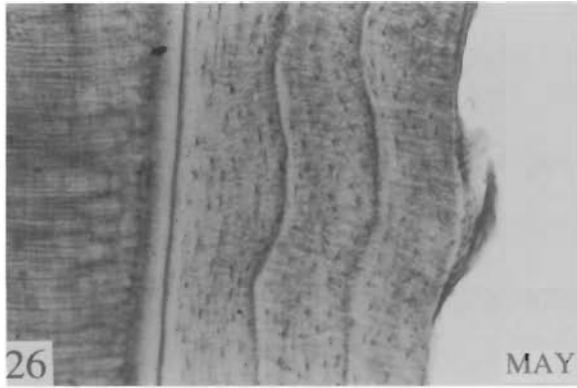


PLATE VII. CEMENTUM ANNULI IN DIFFERENT TOOTH TYPES*

Each of the three tooth types, PM1, PM3, PM4, has two annuli, with the first being close to the dentine. The observation is evidence that the three tooth types can be used interchangeably for cementum aging.

FIG. 32. TOOTH NO. 8905524. JUNE. CEMENTUM AGE 2 YEARS. 140X. UPM1, 1MM ABOVE ROOT TIP. The 1-year annulus is very close to the dentine, but is distinct.

FIG. 33. TOOTH NO. 8905524. 140X. UPM1, 5MM ABOVE ROOT TIP.

FIG. 34. TOOTH NO. 8905524. 140X. UPM3, 1MM ABOVE ROOT TIP.

FIG. 35. TOOTH NO. 8905524. 140X. UPM3, 7MM ABOVE ROOT TIP.

FIG. 36. TOOTH NO. 8905524. 140X. LPM4, 1MM ABOVE ROOT TIP.

FIG. 37. TOOTH NO. 8905524. 140X. LPM4, 10MM ABOVE ROOT TIP, IN ARCH BETWEEN ROOTS.

*All tooth sections were prepared by Matson's Laboratory.

PLATE VII.

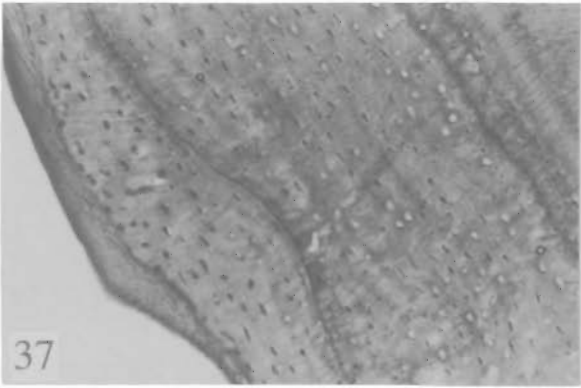
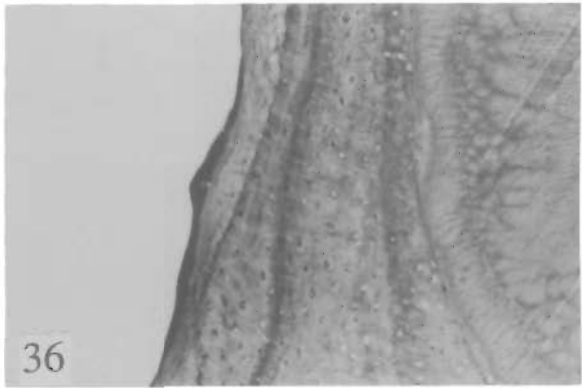
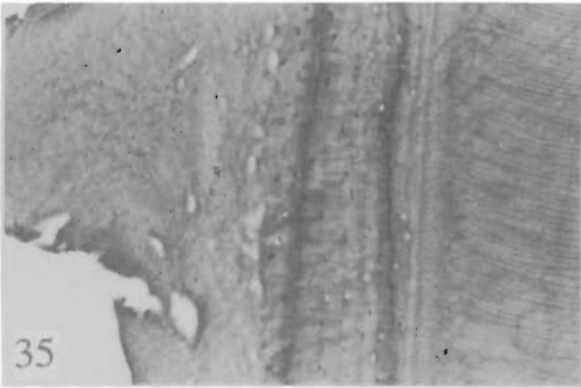
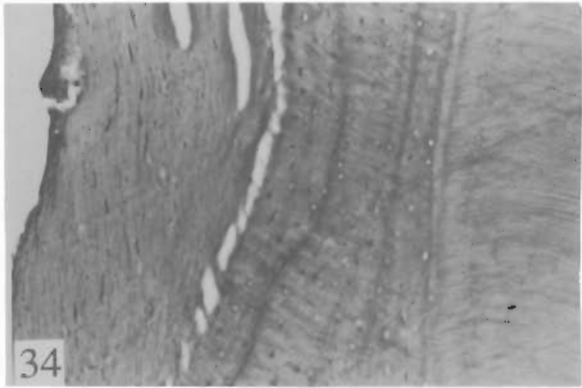
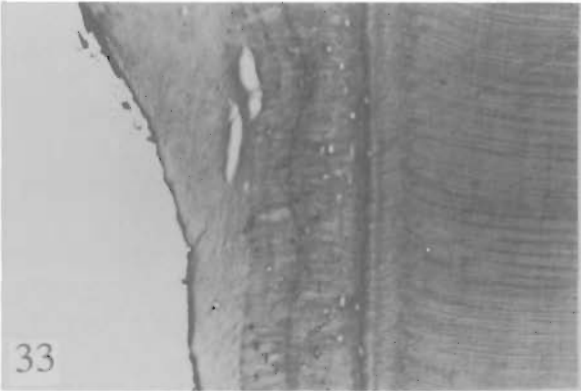
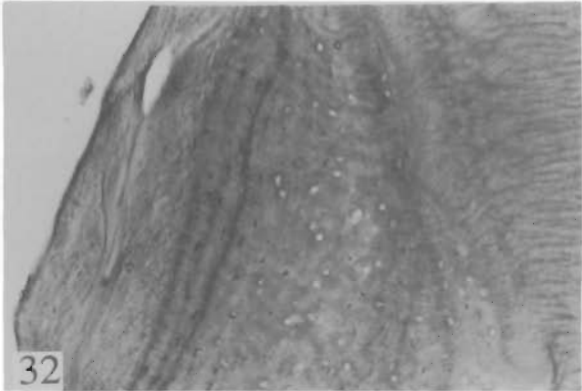


PLATE VIII. TYPICAL AGE CLASSES

Use this plate for a self-test. The plate has photographs paired left and right showing two typical regions for each of three tooth sections. Cover the plate description, age the sections, then refer to the known age.

FIG. 38. SLIDE 7. M. 5/87. KAT 1.4. 53X. ROOT TIP.

FIG. 39. SLIDE 7. 53X. 7MM ABOVE TIP. SAME SIDE.

FIG. 40. SLIDE 2. M. 5/87. KAT 3.4. 53X. 1MM ABOVE TIP. POSTERIOR.

FIG. 41. SLIDE 2. 53X. 8MM ABOVE ROOT TIP. OPPOSITE SIDE, ANTERIOR.

FIG. 42. SLIDE 32. M. 10/77. KAT 4.8. 53X. 2MM ABOVE ROOT TIP, POSTERIOR.

FIG. 43. SLIDE 32. 53X. 6MM ABOVE TIP. SAME SIDE.

PLATE VIII.

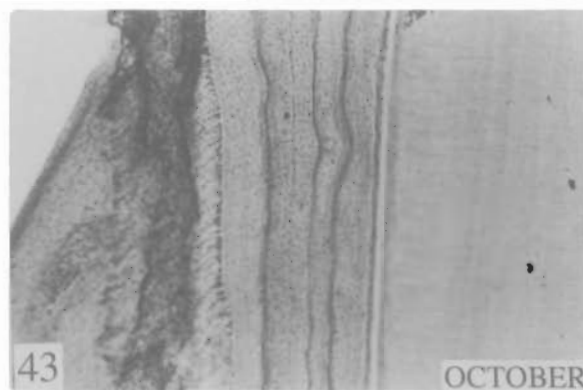
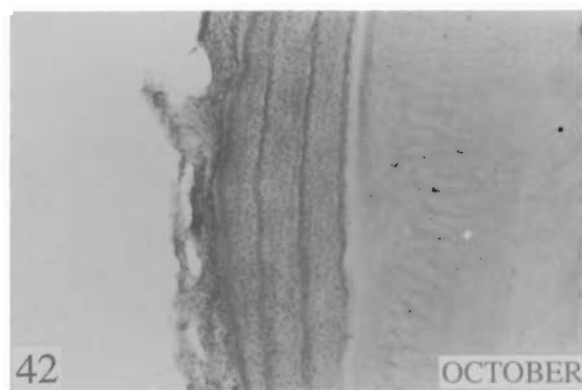
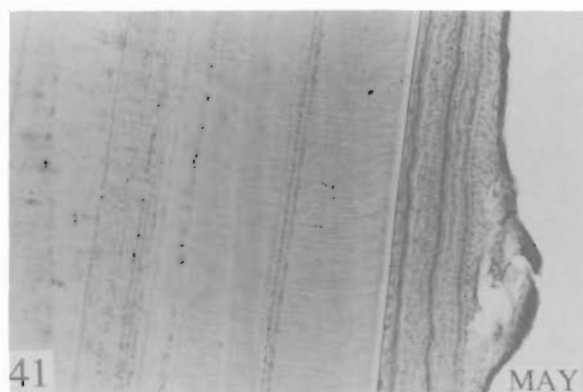
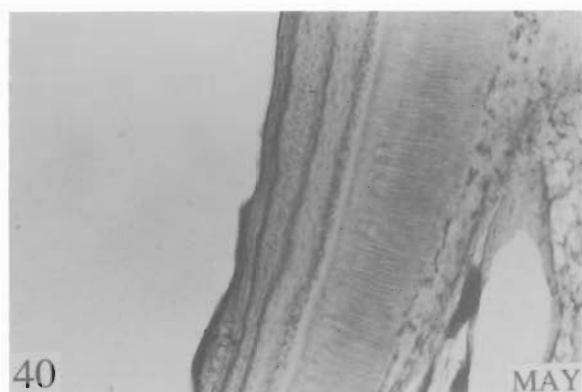
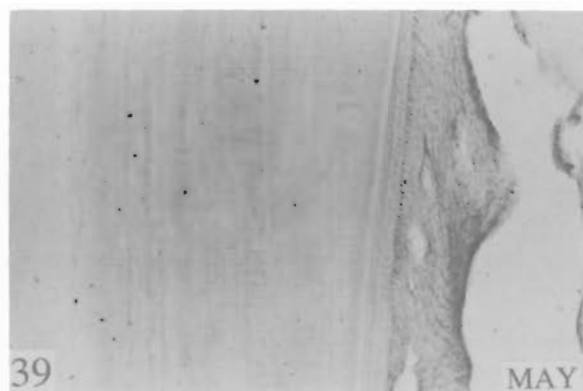
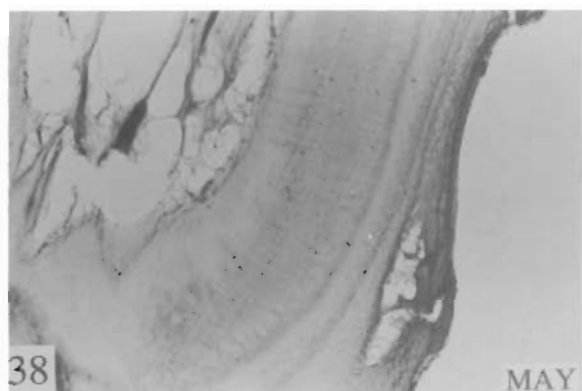


PLATE IX. TYPICAL AGE CLASSES (CONTINUED)

Use this plate for a self-test. The plate has photographs paired left and right showing two typical regions for each of three tooth sections. Cover the plate description, age the sections, then refer to the known age.

FIG. 44. SLIDE 71. F. 6/85. KAT 9.5. 53X. 1MM ABOVE ROOT TIP, ANTERIOR.

FIG. 45. SLIDE 71. 53X. 8MM ABOVE TIP, 2MM BELOW GUMLINE, SAME SIDE.

FIG. 46. SLIDE 62. M. 6/85. KAT 12.5. 53X. 5MM ABOVE ROOT TIP, ANTERIOR.

FIG. 47. SLIDE 62. 53X. POINT OF SECTION IS ADJACENT TO THAT OF FIG. 46.

FIG. 48. SLIDE 20. F. 4/79. KAT 21.3. 53X. 8MM ABOVE ROOT TIP.

FIG. 49. SLIDE 20. 53X. ADJACENT. POINT OF SECTION IS ADJACENT TO THAT OF FIG. 48.

PLATE IX.

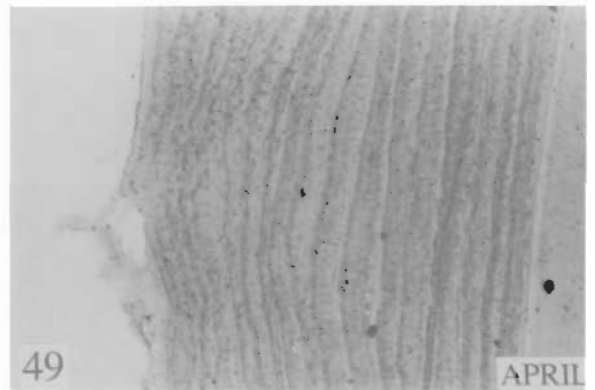
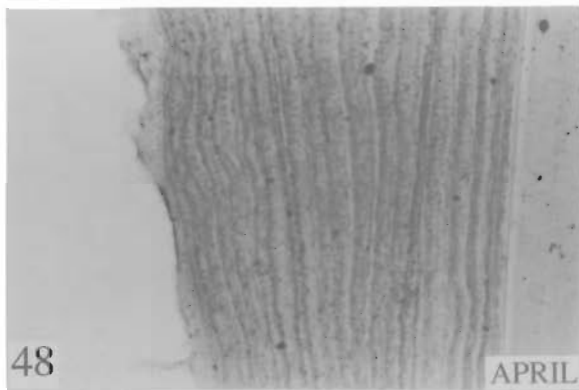
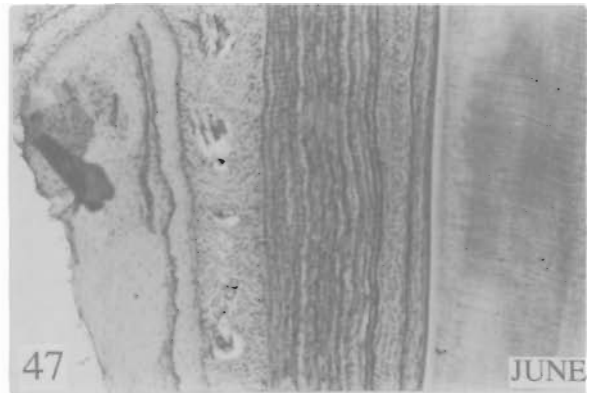
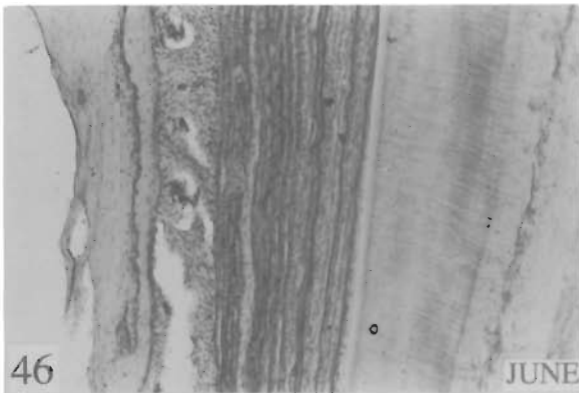
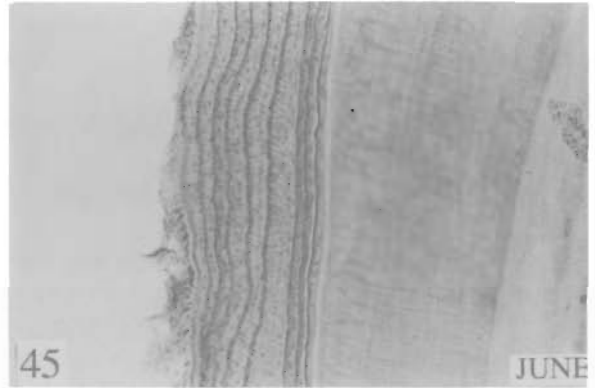
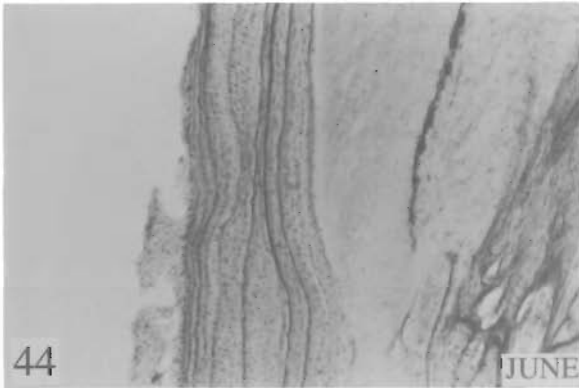


PLATE X. EXAMPLES FOR PRACTICE

Use this plate for a self-test. The plate has photographs paired left and right showing two typical regions for each of three tooth sections. Cover the plate description, age the sections, then refer to the known age.

FIG. 50. SLIDE 69. F. 6/79. KAT 3.5. 140X. ROOT TIP. POSTERIOR.

FIG. 51. SLIDE 69. 140X. 6MM ABOVE ROOT TIP. SAME SIDE.

FIG. 52. SLIDE 64. F. 9/83. KAT 4.5. 140X. 6MM ABOVE ROOT TIP. ANTERIOR.

FIG. 53. SLIDE 64. 140X. 4MM ABOVE TIP. POSTERIOR.

FIG. 54. SLIDE 65. F. 6/85. KAT 6.5. 140X. 3MM ABOVE TIP. POSTERIOR.

FIG. 55. SLIDE 65. 140X. 5MM ABOVE TIP. ANTERIOR.

PLATE X.

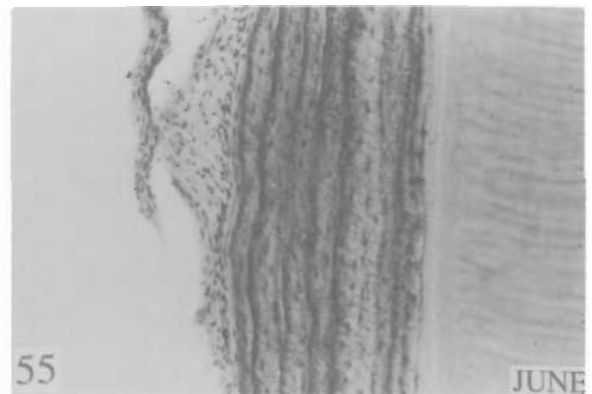
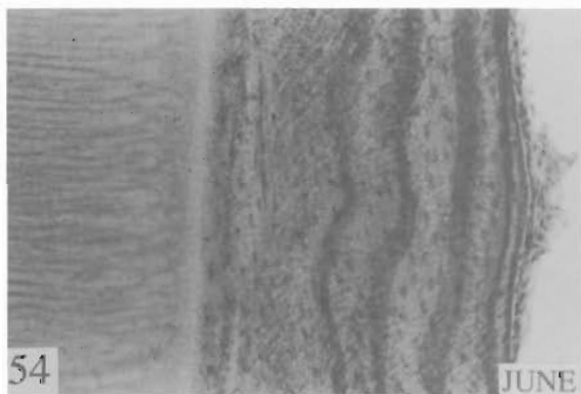
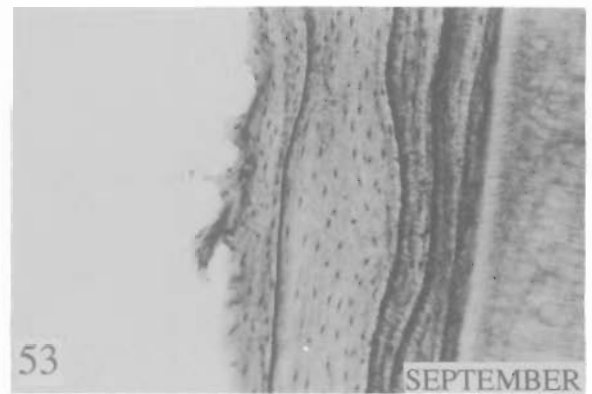
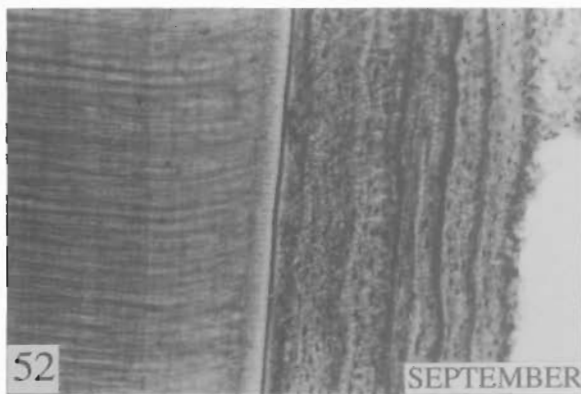
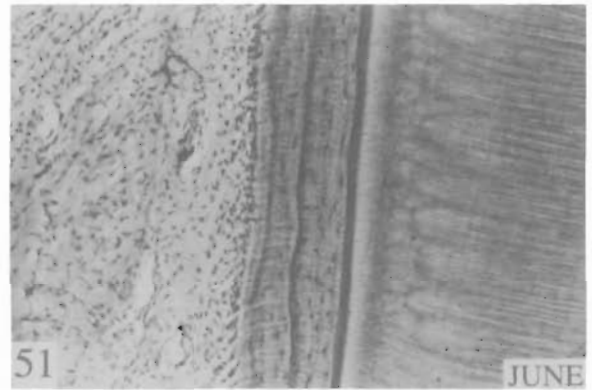
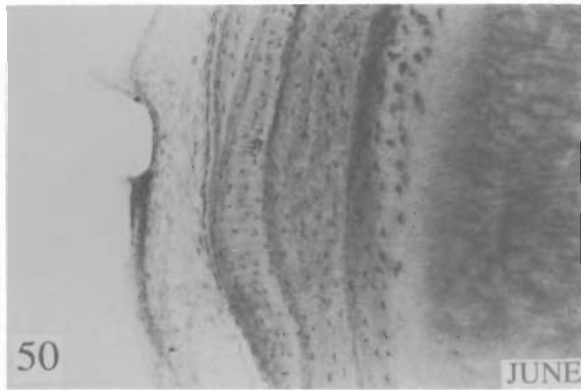


PLATE XI. EXAMPLES FOR PRACTICE (CONTINUED)

Use this plate for a self-test. The plate has photographs paired left and right showing two typical regions for each of three tooth sections. Cover the plate description, age the sections, then refer to the known age.

FIG. 56. SLIDE 66. F. 6/86. KAT 7.5. 140X. 4MM ABOVE TIP. POSTERIOR.

FIG. 57. SLIDE 66. 140X. 5MM ABOVE TIP. ANTERIOR.

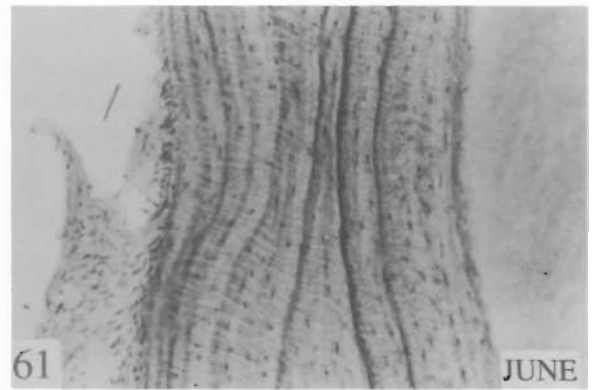
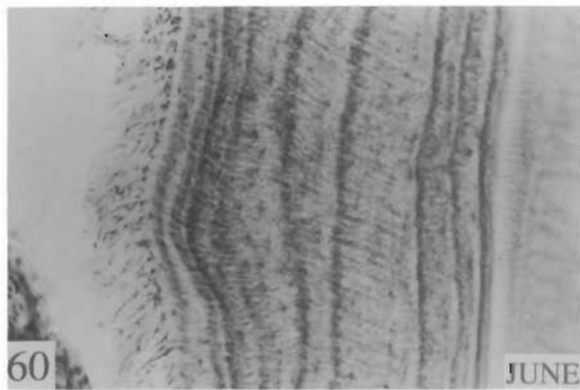
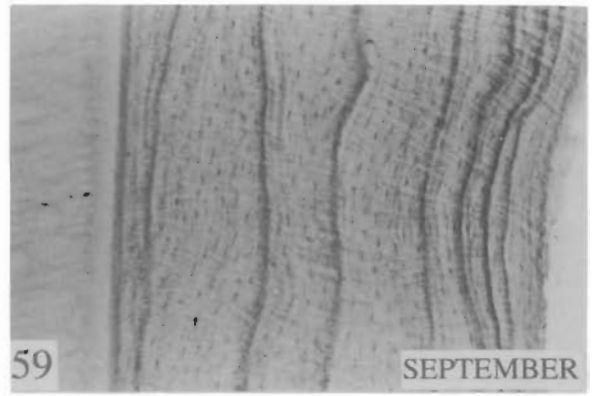
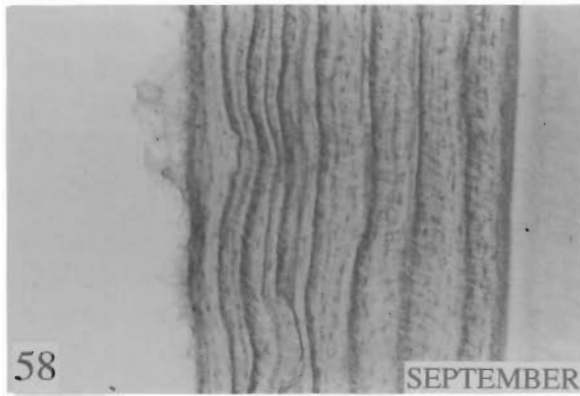
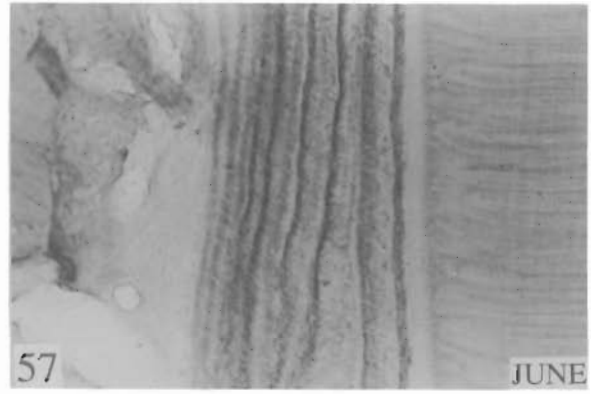
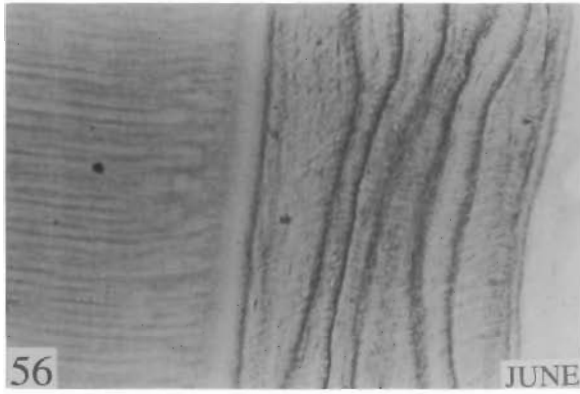
FIG. 58. SLIDE 67. F. 9/85. KAT 8.5. 140X. 7MM ABOVE TIP. ANTERIOR.

FIG. 59. SLIDE 67. 140X. 6MM ABOVE TIP. ANTERIOR.

FIG. 60. SLIDE 71. F. 6/85. KAT 9.5. 140X. 3MM ABOVE GUMLINE. ANTERIOR.

FIG. 61. SLIDE 71. 140X. 1MM ABOVE ROOT TIP. SAME SIDE.

PLATE XI.



TESTING CEMENTUM AGES

Every program of long-term use of cementum ages should establish a test procedure to estimate reliability. The best test is the known age tooth aged without prior knowledge of the ager. The second-best test is the "blind" duplicate (two teeth from the same bear). Third-best is aging of blind duplicates of sections from the same tooth on different slides, and/or blind replicated agings of the same section. Whenever possible, blind tests of the ager should be done with known age and duplicate tooth sections. Errors should be examined, and used as bases for possible revision and refinement of the lab manual for age determination.

Cementum ages can also be tested by reference to other data, such as body weight, and skull size. Whenever these data are available, they should be reviewed along with cementum ages and tested for compatibility.

DEFINING CEMENTUM AGING ACCURACY

The different error factors for different populations and age groups require separate error limits. They must be determined by tests with substantial numbers of known age bears in each age group of each population. Matson's laboratory is attempting to collect data for this use. Presently, the sample sizes required, the duration of the long-term project, and the usefulness of the resulting error definition are not known.

Wildlife management biologists may find useful information about ager error in the evaluation that was conducted by the Alaska Department of Fish and Game and is described below (Page 47). The results from readings of the 75 known age tooth sections by 4 different agers are given in Appendix C.

THE "BACKUP TOOTH"

There is value in having more than a single tooth for each bear. The backup can be used if there is a processing failure with the original tooth, or for testing cementum aging precision (see above). The preferred backup tooth types are, in order of preference, UPM1, LPM1, UPM3, UPM4, LPM4 (Appendix A).

DETERMINING REPRODUCTIVE HISTORY FROM TOOTH SECTIONS

A technique for using tooth sections to determine reproductive history has been described (Carrel 1992, Coy and Garshelis, 1992). Carrel used special instrumentation and determined statistically that the annual light cementum layer of transverse tooth sections was thinner when a female Arizona black bear successfully reared cubs. Coy and Garshelis evaluated light cementum layer thickness in both transverse and longitudinal tooth sections of Minnesota black bears using only a light microscope, without measuring apparatus.

The applicability of the method to other North American bears is not known. Attempts to learn Carrel's technique and apply it to other populations are underway at Matson's Laboratory. Matson

is attempting to determine if reproductive history can be shown using only a microscope without other special instrumentation.

ACKNOWLEDGMENTS

A number of Alaska Department of Fish and Game biologists identified the need to resolve discrepancies in interpretation of cementum layers. Warren Ballard, Mark Chihuly, Enid Goodwin, Harry Reynolds, Chuck Schwartz, and Dick Sellers deserve special mention. ADFG biologists were generous in sharing specimens and data collected during their projects. Dan Timm and Karl Schneider are commended for providing supervisory support during the aging evaluation and writing of this manual. Judy Matson gave unwavering encouragement. Partial funding was provided by the U.S. Fish and Wildlife Service Federal Aid for Wildlife Restoration Program.

LITERATURE CITED

- Carrel, W. K. 1992. Reproductive history in dental cementum of female black bears. Presented at the Ninth International Conference on Bear Research and Management. February 23-28. Missoula, Montana. (Proceedings in press).
- Coy, P. L. and D. L. Garshelis. 1992. Reconstructing reproductive histories of black bears from the incremental layering in dental cementum. *Can. J. Zool.* 70:2150-2160.
- Craighead, J. J., F. C. Craighead, and H. E. McCutchen. 1970. Age determination of grizzly bears from fourth premolar tooth sections. *J. Wildl. Manage.* 34:353-363.
- Goodwin, E. A., and W. B. Ballard. 1985. Use of tooth cementum for age determination of gray wolves. *J. Wildl. Manage.* 49:313-316.
- Johnston, D. H., D. G. Joachim, P. Bachmann, K. V. Kardong, R. E. A. Stewart, L. Dix, M. A. Strickland, I. D. Watt. 1987. Aging furbearers using tooth structure and biomarkers. Pages 228-243 in M. Novak, J. A. Baker, M. E. Obbard, B. Malloch, eds. *Wild furbearer management and conservation in North America*. Ontario Trappers Association, Toronto.
- Kerr, K. 1992. Personal communication. Forest Wildlife Population Research Group. Minnesota Department of Natural Resources. 1201 East HWY 2. Grand Rapids, MN 55744.
- Klevezal, G. A. and S. E. Kleinenberg. 1969. Age determination of mammals from annual layers in teeth and bones. Israel Program for Scientific Translations., Jerusalem, 128pp. (Available from U. S. Dept. Commerce, Clearinghouse for Federal Scientific and Technical Information, Springfield, VA, 22151).
- Marks, S. A. and P. W. Erickson. 1966. Age determination in the black bear. *J. Wildl. Manage.* 30:389-410.
- McLaughlin, C. R., G. J. Matula Jr, R. A. Cross, W. H. Halteman, M. A. Caron, and K. I. Morris. 1990. Precision and accuracy of estimating age of Maine black bears by cementum annuli. *Int. Conf. Bear Res. and Manage.* 8:415-419.

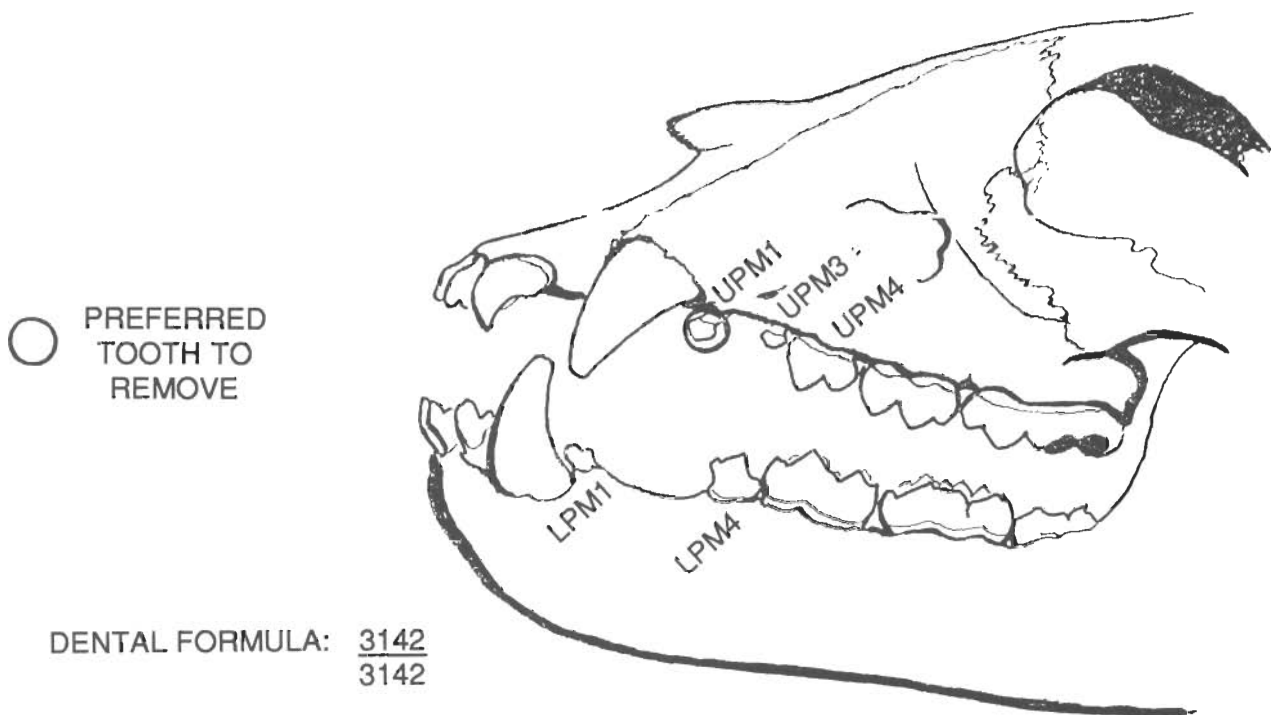
- Mundy, K. R. D. and W. A. Fuller. 1964. Age determination in the grizzly bear. *J. Wildl. Manage.* 28:863-866.
- Myrick, A. C., Jr. 1988. Is tissue resorption and replacement in permanent teeth of mammals caused by stress-induced hypocalcemia. Pages 379-389 in K. P. Pryor and K. S. Norris, eds. *Dolphin societies: Methods of study*. U. C. Press, Berkeley.
- Pearson, A. M. 1975. The northern interior grizzly bear *Ursus arctos* L. *Can. Wildl. Serv. Rep. Ser. No. 34*. Can. Wildl. Serv., Ottawa, 86pp.
- Rausch, R. L. 1969. Morphogenesis and age-related structure of permanent canine teeth in the brown bear, *Ursus arctos* L., in arctic Alaska. *Z. Morph. Tiere.* 66: 167-168.
- Sauer, P. R., S. Free, and S. Browne. 1966. Age determination in black bears from canine tooth sections. *N. Y. Fish and Game J.* 13:125-139.
- Schneider, K. B. 1973. Age determination of sea otter. Final report. Federal aid in wildlife restoration projects W-17-4 and W-17-5, Job 8.10R. Alaska Department of Fish and Game. Juneau.
- Stoneberg, R. P. and C. J. Jonkel. 1966. Age determination of black bears by cementum layers. *J. Wildl. Manage.* 30:411-414.
- Willey, C. H. 1974. Aging black bears from first premolar tooth sections. *J. Wildl. Manage.* 38:97-100.

APPENDIX A

SELECTION AND EXTRACTION OF BEAR TEETH FOR CEMENTUM AGING

Tooth selection

The Upper Premolar Number 1 (UPM1) is preferred for tooth sectioning because it is straight and has a rounded tip. The Lower Premolar Number 1 is more difficult to section in the longitudinal plane because it is curved and has a pointed tip. Preferred after UPM1 are (in order of preference): LPM1, UPM3, UPM4, LPM4. Other teeth may also be used, but may have irregular or indistinct annulus patterns and/or may be too large to process or interpret normally.



DENTAL FORMULA: $\frac{3142}{3142}$

P2 & P3 OFTEN ABSENT

Tooth Extraction

Bear teeth can be easily extracted from either recently killed or tranquilized live bears using the following technique:

1. Position the bear's head so that you can easily access the tooth and get good leverage for pulling. The bear's jaw should be opened wide. If the bear is alive and tranquilized, place a stout branch between the upper and lower molars.

Heads of dead bears should not be frozen before a tooth is extracted, because of the time and inconvenience of allowing complete thawing before the jaws can be manipulated.

2. Gently push a tooth elevator between the tooth and the gum at an angle parallel to the long axis of the tooth. Slide it around the tooth and apply enough pressure to loosen the tooth. Do not use the elevator to pry the tooth out of the jaw. Be careful that you do not gouge or scratch the tooth while using the elevator. Remove the elevator.
3. Grasp the crown of the tooth firmly with a dental extractor and make a hard, sharp pull in line with the long axis of the tooth. Pull the tooth straight out of its socket (Note: lower premolar #1 must be pulled at an angle toward the front of the jaw). If the tooth cannot be pulled without undue effort, use the elevator to loosen it more. Be careful not to break the root during the tooth extraction. If it breaks, pull another tooth.
4. Put the extracted tooth into a small envelope that is marked with the tooth type (e.g. UPM1), the species and sex of the bear, date of kill or date of tooth extraction from live bear, location of kill or capture, and any applicable identification numbers. Seal the envelope.
5. Teeth should remain in their envelopes and be stored in a cool, dry place until they are sent to the aging laboratory for analysis. If teeth are to be stored for more than a few weeks before processing, they can be kept frozen to minimize any post-mortem tissue changes.

Note: A thin-bladed pocket knife and pliers can be substituted for a dental elevator and tooth extractor, but the chances of gouging, scraping, and/or crushing a tooth are greatly increased. Any tooth that is damaged during extraction may not provide accurate age data.

Tooth Extraction From Dried Material

Teeth are more difficult to extract from the dried mandible or skull. Soak the specimen in hot water at 80-90 degrees centigrade for 2-4 hours to soften the tissue. Then, apply the procedure recommended above for fresh specimens. The water bath temperature should be

kept below boiling to avoid tissue damage and diminished histological staining. No chemical agent should be added to the plain hot water bath.

APPENDIX B

SECTIONING AND STAINING TECHNIQUES FOR PM1 TEETH

Alaska Department of Fish and Game Method

Many of the known age preparations that were studied for the evaluation, that is the basis for this manual were decalcified, frozen sections made with a cryostat and stained using Harris' modified hematoxylin stain with hot bath (Goodwin and Ballard 1985). Sections prepared by this method were of excellent quality, with good differentiation between annuli and light cementum.

Technique Standardization

Histological techniques, like kitchen recipes, are passed along from one person to another. Textbooks give basic formulas and scheduling, but do not provide guidelines for the standardizing that is necessary for each laboratory because of its unique histological material, laboratory environment, and chemical stores. When laboratory techniques are not standardized, variation of the finished preparations can interfere with the usefulness of the histological product.

Matson's Laboratory keeps a complete, written description of all steps in our process for preparing tooth sections for aging. Chemical preparations, processing schedules, solution temperatures, and timing are described with defined limits. The method is revised whenever experience or controlled study (or serendipity!) shows that the revision is an improvement.

Tooth Section Preparation: Laboratory Methods that require standardization to obtain section characteristics that are uniform over time

1. Exposure of teeth to chemicals, prior to decalcification. No chemical substance should be used, as an aid to cleaning the tooth or removing it from bone, without first conducting a controlled study to determine whether the chemical affects physical or chemical characteristics of the tooth. Bleach solutions are commonly used to clean skulls/bones but can chemically remove cementum tissue.
2. Decalcification
 - a. Formula for working solution
 - b. Number of uses for a working solution; replenishment
 - c. Volume of working solution per tooth
 - d. Temperature of working solution
 - e. Length of time in working solution

- f. Trimming to select plane of sectioning
- g. Test for completeness of decalcification
3. Post-decalcification treatment
 - a. Rinse
 - b. Storage of the decalcified tooth
4. Pre-sectioning processing
5. Sectioning
 - a. Knife sharpness
 - b. Section thickness
6. Staining
 - a. Age and activity of stain stock solution
 - b. Stain working solution preparation
 - c. Temperature of stain working solution
 - d. Number of uses permitted for stain working solution
 - e. Rinsing and differentiating solutions:
 - Chemical composition
 - Number of uses
 - Water purity and temperature
 - Duration of section exposure to each solution
 - Visual control of differentiation process
7. Accuracy control check for tooth identification. Every time a tooth or tooth section is handled.

The Paraffin Method

The following generalized method is used at Matson's Laboratory. Complete details are unpublished proprietary information and include standards and limits for each of the

processing steps listed above. A method for preparing and staining frozen sections of decalcified sea otter teeth was described by Schneider (1973), and is similar to Matson's method.

Teeth are treated in 10% formalin, decalcified in hydrochloric acid and rinsed in tap water. Decalcified teeth are precisely trimmed with a razor blade to very near the final sectioning plane. Two planes of section are used: 1) Mid-sagittal (preferred); 2) Longitudinal in any plane that passes through the pulp cavity and includes the area near the crown as well as the complete root tip. The second plane is used in cases where the root tip is so curved that it would not be included with the greater portion of the tooth when sectioned in the mid-sagittal plane. This modification, to compensate for root tip curvature, substitutes for the Department's frozen section laboratory procedure of straightening the curved root tip during freezing. A portion of the tooth crown may be trimmed off and discarded, but it is of special importance to section the entire tooth, including at least a portion of the crown and all of the root, extending from the gumline to the tip. Earlier standard procedure at Matson's was section only a 6-8mm portion of the root tip, but this omits points of the tooth root that may contain the most distinct arrangement of annuli.

Trimmed, decalcified teeth are placed in a fresh acid solution for two days, then tested for decalcification completeness. They are treated a second time in 10% formalin, rinsed in tap water, dehydrated in isopropyl alcohol, cleared in toluene, and embedded in paraffin.

Embedded teeth are sectioned at 14 microns. Sections are mounted on microscope slides, dried, and stained with Giemsa blood stain (Wolbach formula). The working solution is prepared from stock solution using proportions similar to those described by Schneider (1973). Staining is controlled by using sections from the oldest bears as guidelines, with the goal of having a clear differentiation between annuli and light cementum at the periphery of the sections where annuli are closely spaced, complex, and difficult to count.

Stained slides are cleared in toluene, and a no. 1-1/2 coverglass is applied using Lipshaw Mounting Media.

Optical Instruments For Tooth Section Examination

The Alaska Department of Fish and Game has used two optical methods for tooth section examination: 1) Dissecting microscope, 2) microfiche reader. An advantage of both systems is that more of the tooth section can be seen at one time. The entire section can be viewed in the microfiche. The dissecting scope can be used either to view the whole section, or zoomed to view a portion of the section at greater magnifications (30X - 100X).

A disadvantage of both the microfiche and dissecting scope is lower resolving power, so there is less ability to view magnified images with the clear detail that is possible with the compound microscope. The microfiche image has a grainy appearance. The dissecting scope lighting system is not adequate for good resolution of fine detail because light from the source is reflected off a diffusing mirror under the stage, and there is no light-focusing condenser.

The lessened amount of detail in the magnified image has been described by users as an advantage of both the microfiche and dissecting scope. Experienced users feel that greater detail confuses the viewer and makes difficult the identification of the most prominent dark growth layers of the tooth section.

Matson's Laboratory uses a Leitz compound microscope equipped with coated flatfield objectives to minimize chromatic and spherical aberration. The optical system is of the highest quality, suitable for any critical use. Matson relies upon the resolving power of the compound microscope to identify the very small separation between the 1-year growth layer and the dentine cementum junction (see below), and to identify the closely spaced growth layers at the periphery of tooth sections of older bears.

Experienced observers at the Alaska Department of Fish and Game were better able to use the microfiche and dissecting scope to accurately age tooth sections from young bears than was Matson. This observation suggests that experience may improve the technician's ability to use these systems with good aging accuracy, although there have been no controlled studies of the relative advantages of different optical systems.

LAB SAFETY AND HAZARDOUS WASTES

The laboratory must be equipped with fume hoods. Sources of hazardous or nuisance fumes include formaldehyde, toluene, xylene, isopropyl alcohol. Fume levels should be tested by a **qualified person**, and fume concentration should be well below established limits.

All waste chemicals should be disposed of by methods **that are in compliance** with all state and federal regulations for hazardous waste disposal. Some biological dyes, including Giemsa and **Hematoxylin, are biodegradable and** may be poured into sewer systems. Acid solutions must be neutralized before disposal.

APPENDIX C

COMPARISON BETWEEN KNOWN AGES AND THE CEMENTUM AGES OF FOUR EXPERIENCED TECHNICIANS

In 1988, the Alaska Department of Fish and Game (ADFG) evaluated the accuracy and precision of experienced tooth section readers in determining the age of brown bear teeth from various areas in Alaska.

Methods

A sample of 75 prepared slides with stained, longitudinal sections of premolar teeth from known age brown bears were obtained from the ADFG archives. Teeth were collected from 1971-1987 and laboratory processing was done by ADFG technicians. All of the bears from which the teeth were taken were originally observed by ADFG researchers as cubs-of-the-year, yearlings, or 2-year-olds. It was assumed that biologists could accurately ascertain the age of the cubs in the field, and that the identification markings done at initial capture assured correct individual identification when "known age" teeth were collected upon recapture at a later date.

Four experienced readers agreed to participate in the evaluation. Each was asked to participate in 3 separate blind trials with the entire sample of tooth sections mounted on microscope slides. Each trial was conducted at the reader's own laboratory using whatever method they normally used (microscope, microfiche reader, etc). Readers were given a box of numbered slides, a list of slide numbers, sex, area of collection, month of collection and skull size. When the tooth sections were read and returned, the slides were shuffled randomly and new data sheets were developed to correspond to the new sequence.

Results

The mean of 4 agers' cementum aging precision (agreement among successive agings of the same tooth) was determined for 8 age groupings, and is shown in Graph A. Precision, which measures repeatability but not correctness, was greatest for the yearling age class, and declined as age increased. For example, approximately 80% of yearling tooth sections were read the same all 3 times. In the 10+ age category, all 3 readings were the same for only about 30% of the sections. Two of the 3 readings were the same for more than 90% of tooth sections from bears aged 5 years or less.

Cementum aging accuracy (agreement between cementum age and known age) is shown in Graph B. Mean deviation from known age was calculated for all agers' readings of all tooth sections in each of 8 age groupings. Cementum ages of all agers were similarly accurate for the age groupings 5 years and below. Two of the 4 agers' results were more accurate for older age classes than were the results of the other two. Cementum aging accuracy is in part due to consistent application of the "model" (standardized procedures and interpretations) that is described in this manual for brown bear first premolar tooth sections.

Table 1 gives all agers' readings of all tooth sections in the known age sample. There was greatest agreement among sections of younger bears, and least among those of older.

TABLE 1. ALASKA BROWN BEAR PM1 TOOTH SECTION CEMENTUM AGE COMPARED WITH KNOWN AGE • THREE INDEPENDENT DETERMINATIONS BY EACH OF FOUR AGERS

| SLIDE NO. | KNOWN AGE | | | CEMENTUM AGE* | | | | | | | | | |
|-----------|-----------|------|------|---------------|------|------|------|------|------|------|------|------|------|
| | 1-1 | 1-2 | 1-3 | 2-1 | 2-2 | 2-3 | 3-1 | 3-2 | 3-3 | 4-1 | 4-2 | 4-3 | |
| 1 | 6.4 | 5.4 | 5.4 | 5.4 | 5.4 | 5.4 | 5.4 | 6.4 | 6.4 | 6.4 | 5.4 | 5.4 | 5.4 |
| 2 | 3.4 | 3.4 | 3.4 | 2.4 | 2.4 | 3.4 | 2.4 | 3.4 | 3.4 | 3.4 | 3.4 | 3.4 | 3.4 |
| 3 | 2.9 | 2.9 | 3.9 | 2.9 | 2.9 | 2.9 | 2.9 | 2.9 | 2.9 | 2.9 | 2.9 | 2.9 | 2.9 |
| 4 | 2.5 | 3.5 | 3.5 | 2.5 | 2.5 | 3.5 | 2.5 | 4.5 | 2.5 | 2.5 | 2.5 | 3.5 | 2.5 |
| 5 | 3.4 | 2.4 | 2.4 | 2.4 | 2.4 | 2.4 | 2.4 | 3.4 | 3.4 | 3.4 | 3.4 | 3.4 | 3.4 |
| 6 | 4.4 | 3.4 | 4.4 | 3.4 | 4.4 | 3.4 | 2.4 | 4.4 | 4.4 | 4.4 | 4.4 | 4.4 | 4.4 |
| 7 | 1.4 | 0.4 | 1.4 | 1.4 | 1.4 | 2.4 | 1.4 | 1.4 | 1.4 | 1.4 | 2.4 | 2.4 | 2.4 |
| 8 | 21.3 | 16.3 | 15.3 | 18.4 | 15.3 | 16.3 | 17.3 | 20.3 | 20.3 | 19.3 | 18.3 | 22.3 | 21.3 |
| 9 | 2.5 | 1.5 | 1.5 | 1.5 | 2.5 | 3.5 | 2.5 | 3.5 | 3.5 | 2.5 | 1.5 | 2.5 | 2.5 |
| 10 | 2.4 | 1.4 | 1.4 | 1.4 | 2.4 | 2.4 | 2.4 | 2.4 | 2.4 | 2.4 | 2.4 | 2.4 | 2.4 |
| 11 | 4.5 | 2.5 | 3.5 | 3.5 | 2.5 | 2.5 | 2.5 | 3.5 | 3.5 | 3.5 | 3.5 | 4.5 | 4.5 |
| 12 | 4.5 | 3.5 | 3.5 | 3.5 | 3.5 | 4.5 | 4.5 | 4.5 | 4.5 | 4.5 | 4.5 | 4.5 | 4.5 |
| 13 | 1.4 | 0.4 | 0.4 | 0.4 | 0.4 | 0.4 | 0.4 | 1.4 | 1.4 | 1.4 | 1.4 | 1.4 | 1.4 |
| 14 | 1.4 | 1.4 | 1.4 | 1.4 | 2.4 | 2.4 | 1.4 | 2.4 | 1.4 | 1.4 | 2.4 | 2.4 | 2.4 |
| 15 | 4.3 | 3.3 | 3.3 | 3.3 | 3.3 | 3.3 | 4.3 | 4.3 | 4.3 | 4.3 | 4.3 | 4.3 | 4.3 |
| 16 | 1.6 | 1.6 | 1.6 | 1.6 | 1.6 | 1.6 | 1.6 | 1.6 | 1.6 | 1.6 | 1.6 | 1.6 | 1.6 |
| 17 | 1.3 | 1.3 | 0.3 | 0.3 | 0.3 | 1.3 | 0.3 | 1.3 | 1.3 | 1.3 | 1.3 | 1.3 | 1.3 |
| 18 | 1.4 | 0.4 | 0.4 | 0.4 | 1.4 | 1.4 | 1.4 | 1.4 | 2.4 | 2.4 | 1.4 | 1.4 | 2.4 |
| 19 | 7.4 | 3.4 | 4.4 | 3.4 | 4.4 | 4.4 | 3.4 | 7.4 | 6.4 | 7.4 | 3.4 | 7.4 | 7.4 |
| 20 | 21.3 | 17.3 | 19.3 | 18.3 | 19.3 | 19.3 | 19.3 | 20.3 | 20.3 | 20.3 | 20.3 | 20.3 | 20.3 |
| 21 | 21.3 | 17.3 | 18.3 | 18.3 | 16.3 | 18.3 | 19.3 | 20.3 | 20.3 | 20.3 | 19.3 | 20.3 | 20.3 |
| 22 | 3.4 | 2.4 | 2.4 | 2.4 | 3.4 | 3.4 | 3.4 | 3.4 | 3.4 | 3.4 | 4.4 | 4.4 | 3.4 |
| 23 | 1.4 | 0.4 | 0.4 | 0.4 | 0.4 | 0.4 | 0.4 | 0.4 | 0.4 | 0.4 | 1.4 | 1.4 | 1.4 |
| 24 | 1.4 | 0.4 | 0.4 | 0.4 | 0.4 | 0.4 | 0.4 | 0.4 | 0.4 | 0.4 | 1.4 | 1.4 | 1.4 |
| 25 | 1.4 | 0.4 | 0.4 | 0.4 | 0.4 | 1.4 | 0.4 | 1.4 | 1.4 | 1.4 | 1.4 | 1.4 | 1.4 |
| 26 | 1.8 | 1.8 | 1.8 | 1.8 | 2.8 | 2.8 | 2.8 | 2.8 | 2.8 | 2.8 | 1.8 | 4.8 | 5.8 |
| 27 | 1.5 | 0.5 | 0.5 | 0.5 | 0.5 | 1.5 | 1.5 | 1.5 | 1.5 | 1.5 | 1.5 | 1.5 | 1.5 |
| 28 | 1.5 | 0.5 | 0.5 | 0.5 | 1.5 | 1.5 | 1.5 | 1.5 | 1.5 | 1.5 | 1.5 | 1.5 | 1.5 |
| 29 | 2.8 | 2.8 | 2.8 | 2.8 | 2.8 | 1.8 | 1.8 | 2.8 | 2.8 | 2.8 | 2.8 | 2.8 | 2.8 |
| 30 | 2.5 | 1.5 | 1.5 | 1.5 | 2.5 | 2.5 | 2.5 | 2.5 | 2.5 | 2.5 | 2.5 | 2.5 | 2.5 |

*1-1 = Reader #1, reading 1; 1-2 = Reader # 1, reading 2; etc.

(continued next page)

TABLE 1 continued.

| SLIDE KNOWN NO. | CEMENTUM AGE* | | | | | | | | | | | | |
|--------------------|---------------|------|------|------|------|------|-----|------|------|------|------|------|------|
| | AGE 1-1 | 1-2 | 1-3 | 2-1 | 2-2 | 2-3 | 3-1 | 3-2 | 3-3 | 4-1 | 4-2 | 4-3 | |
| 31 | 3.8 | 2.8 | 2.8 | 2.8 | 2.8 | 2.8 | 2.8 | 3.8 | 2.8 | 2.8 | 2.8 | 3.8 | 3.8 |
| 32 | 4.8 | 3.8 | 3.8 | 3.8 | 3.8 | 3.8 | 3.8 | 4.8 | 4.8 | 4.8 | 4.8 | 4.8 | 4.8 |
| 33 | 3.4 | 4.4 | 4.4 | 4.4 | 3.4 | 3.4 | 4.4 | 4.4 | 4.4 | 4.4 | 4.4 | 5.4 | 5.4 |
| 34 | 8.8 | 7.8 | 7.8 | 7.8 | 8.8 | 7.8 | 7.8 | 8.8 | 8.8 | 8.8 | 7.8 | 8.8 | 8.8 |
| 35 | 2.8 | 2.8 | 3.8 | 2.8 | 2.8 | 2.8 | 2.8 | 2.8 | 2.8 | 2.8 | 3.8 | 3.8 | 3.8 |
| 36 | 4.8 | 3.8 | 3.8 | 4.8 | 4.8 | 4.8 | 4.8 | 4.8 | 4.8 | 4.8 | 4.8 | 4.8 | 4.8 |
| 37 | 4.8 | 4.8 | 3.8 | 3.8 | 3.8 | 4.8 | 4.8 | 4.8 | 4.8 | 4.8 | 6.8 | 6.8 | 5.8 |
| 38 | 2.6 | 3.6 | 3.6 | 3.6 | 2.6 | 2.6 | 2.6 | 2.6 | 3.6 | 2.6 | 2.6 | 3.6 | 2.6 |
| 39 | 2.8 | 4.8 | 2.8 | 2.8 | 2.8 | 2.8 | 2.8 | 3.8 | 2.8 | 2.8 | 2.8 | 3.8 | 2.8 |
| 40 | 2.5 | 3.5 | 4.5 | 3.5 | 2.5 | 3.5 | 2.5 | 3.5 | 3.5 | 3.5 | 4.5 | 4.5 | 3.5 |
| 41 | 9.4 | 8.4 | 8.4 | 8.4 | 8.4 | 9.4 | 7.4 | 8.4 | 9.4 | 8.4 | 9.4 | 9.4 | 9.4 |
| 42 | 4.4 | 6.4 | 6.4 | 6.4 | 5.4 | 6.4 | 3.4 | 3.4 | 3.4 | 3.4 | 7.4 | 10.4 | 10.4 |
| 43 | 6.8 | 7.8 | 4.8 | 8.8 | 6.8 | 7.8 | 6.8 | 6.8 | 7.8 | 6.8 | 6.8 | 8.8 | 6.8 |
| 44 | 5.5 | 4.5 | 5.5 | 4.5 | 5.5 | 5.5 | 5.5 | 5.5 | 5.5 | 5.5 | 5.5 | 6.5 | 6.5 |
| 45 | 5.4 | 4.4 | 5.4 | 5.4 | 5.4 | 6.4 | 4.4 | 6.4 | 5.4 | 5.4 | 6.4 | 6.4 | 6.4 |
| 46 | 5.4 | 6.4 | 5.4 | 5.4 | 6.4 | 4.4 | 4.4 | 5.4 | 6.4 | 5.4 | 5.4 | 11.4 | 11.4 |
| 47 | 7.5 | 6.5 | 6.5 | 6.5 | 5.5 | 5.5 | 5.5 | 6.5 | 6.5 | 6.5 | 5.5 | 6.5 | 6.5 |
| 48 | 5.4 | 3.4 | 3.4 | 3.4 | 4.4 | 4.4 | 4.4 | 4.4 | 4.4 | 4.4 | 4.4 | 5.4 | 5.4 |
| 49 | 4.3 | 4.3 | 4.3 | 4.3 | 4.3 | 4.3 | 4.3 | 4.3 | 5.3 | 4.3 | 10.3 | 9.3 | 6.3 |
| 50 | 4.5 | 3.5 | 3.5 | 3.5 | 3.5 | 3.5 | 3.5 | 4.5 | 4.5 | 4.5 | 3.5 | 4.5 | 4.5 |
| 51 | 4.5 | 3.5 | 3.5 | 3.5 | 3.5 | 3.5 | 3.5 | 4.5 | 4.5 | 4.5 | 3.5 | 4.5 | 4.5 |
| 52 | 4.3 | 4.3 | 4.3 | 4.3 | 4.3 | 4.3 | 4.3 | 5.3 | 5.3 | 5.3 | 5.3 | 6.3 | 6.3 |
| 53 | 3.8 | 3.8 | 3.8 | 3.8 | 3.8 | 3.8 | 3.8 | 3.8 | 3.8 | 3.8 | 3.8 | 3.8 | 4.8 |
| 54 | 4.8 | 3.8 | 3.8 | 3.8 | 4.8 | 4.8 | 4.8 | 4.8 | 4.8 | 4.8 | 5.8 | 5.8 | 5.8 |
| 55 | 2.3 | 2.3 | 2.3 | 2.3 | 2.3 | 2.3 | 2.3 | 2.3 | 3.3 | 3.3 | 2.3 | 3.3 | 3.3 |
| 56 | 6.5 | 5.5 | 6.5 | 5.5 | 5.8 | 5.5 | 6.5 | 6.5 | 5.5 | 6.5 | 6.5 | 6.5 | 6.5 |
| 57 | 5.5 | 3.5 | 4.5 | 4.5 | 3.5 | 3.5 | 3.5 | 4.5 | 4.5 | 4.5 | 4.5 | 5.5 | 5.5 |
| 58 | 5.5 | 4.5 | 4.5 | 4.5 | 4.5 | 4.5 | 4.5 | 5.5 | 4.5 | 5.5 | 5.5 | 5.5 | 5.5 |
| 59 | 6.5 | 6.5 | 5.5 | 5.5 | 4.5 | 4.5 | 4.5 | 6.5 | 6.5 | 6.5 | 6.5 | 6.5 | 6.5 |
| 60 | 3.5 | 6.5 | 5.5 | 6.5 | 6.8 | 6.5 | 6.5 | 6.5 | 6.5 | 6.5 | 7.5 | 7.5 | 7.5 |
| 61 | 2.5 | 2.5 | 1.5 | 3.5 | 3.5 | 2.5 | 2.5 | 2.5 | 3.5 | 2.5 | 3.5 | 2.5 | 3.5 |
| 62 | 12.5 | 12.5 | 13.5 | 11.5 | 11.5 | 10.5 | 7.5 | 13.5 | 14.5 | 14.5 | 12.5 | 13.5 | 13.5 |
| 63 | 8.5 | 7.5 | 7.5 | 7.5 | 6.4 | 6.5 | 6.5 | 8.5 | 7.5 | 7.5 | 8.5 | 8.5 | 8.5 |
| 64 | 4.5 | 4.5 | 5.5 | 5.5 | 4.8 | 4.5 | 5.5 | 4.5 | 5.5 | 4.5 | 6.5 | 6.5 | 6.5 |
| 65 | 6.5 | 5.5 | 5.5 | 7.5 | 4.5 | 5.5 | 5.5 | 5.5 | 6.5 | 5.5 | 6.5 | 6.5 | 6.5 |

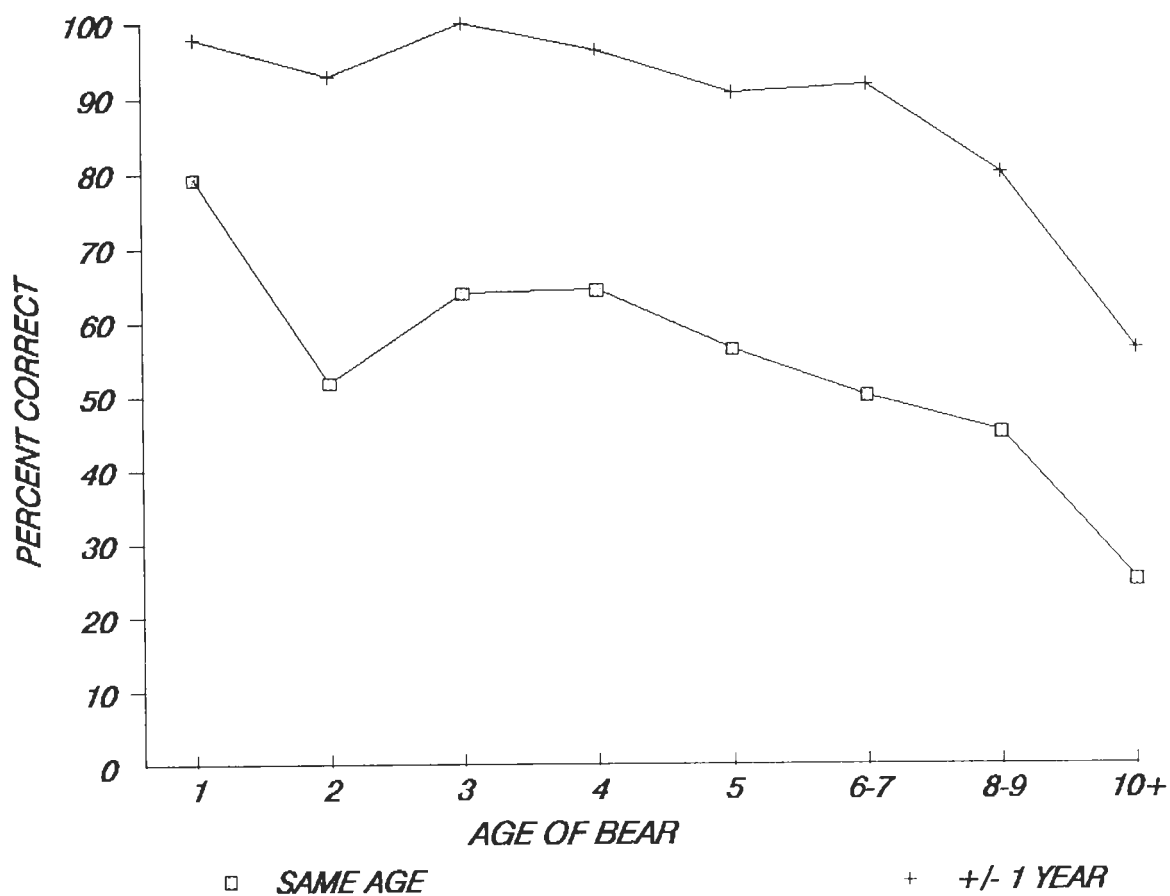
*1-1 = Reader #1, reading 1; 1-2 = Reader # 1, reading 2; etc.

(continued next page)

TABLE 1 continued.

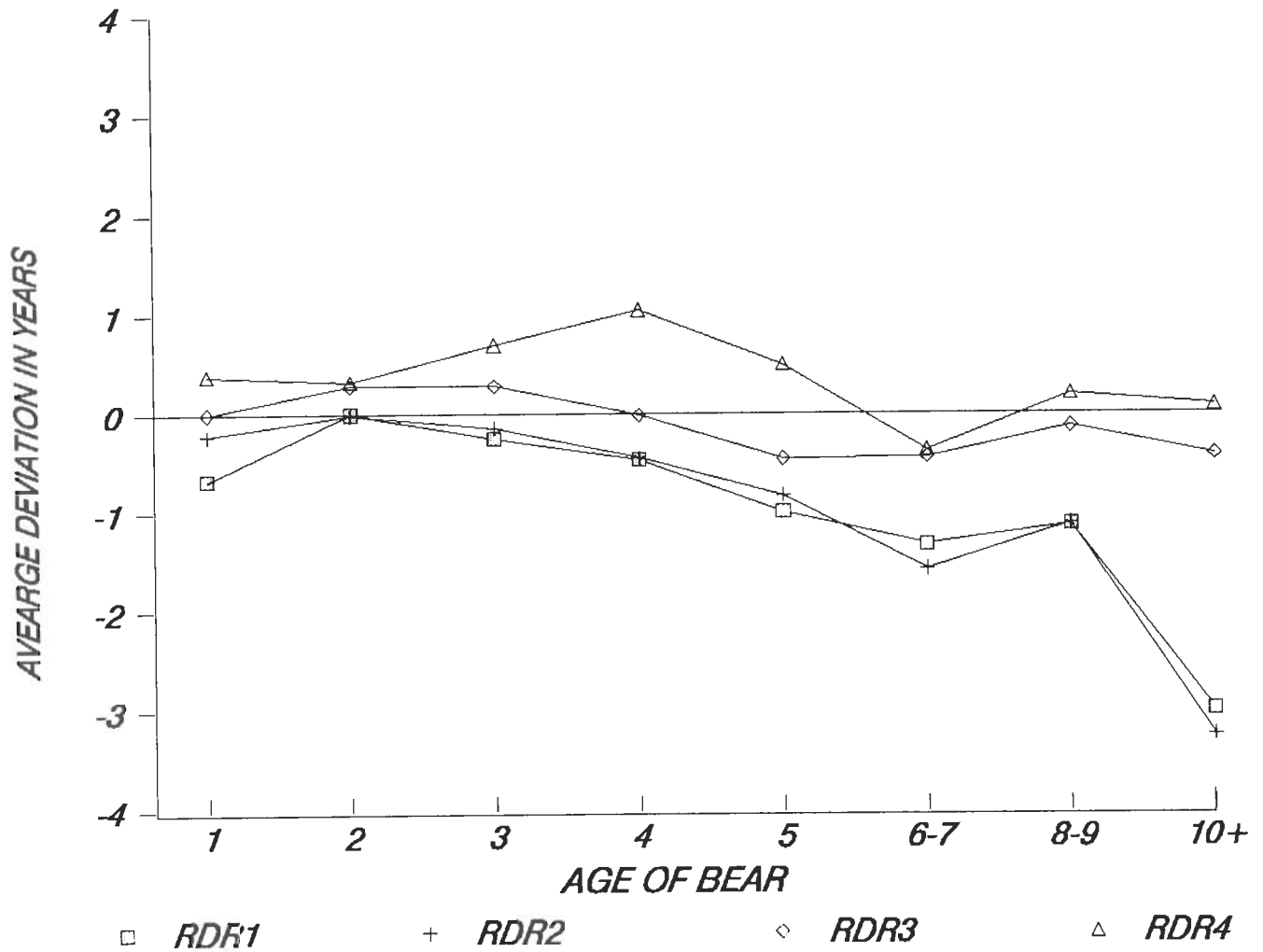
| SLIDE KNOWN NO. | CEMENTUM AGE* | | | | | | | | | | | | |
|--------------------|---------------|-----|-----|-----|-----|-----|-----|-----|-----|-----|------|-----|-----|
| | AGE 1-1 | 1-2 | 1-3 | 2-1 | 2-2 | 2-3 | 3-1 | 3-2 | 3-3 | 4-1 | 4-2 | 4-3 | |
| 66 | 7.5 | 6.5 | 6.5 | 7.5 | 6.5 | 6.5 | 6.5 | 7.5 | 7.5 | 7.5 | 8.5 | 8.5 | 8.5 |
| 67 | 8.5 | 7.5 | 7.5 | 8.5 | 8.8 | 8.5 | 7.5 | 9.5 | 8.5 | 9.5 | 10.5 | 9.5 | 9.5 |
| 68 | 3.5 | 1.5 | 1.5 | 2.5 | 2.4 | 1.5 | 2.5 | 3.5 | 2.5 | 2.5 | 3.5 | 3.5 | 3.5 |
| 69 | 3.5 | 2.5 | 2.5 | 2.5 | 2.5 | 3.5 | 2.5 | 3.5 | 3.5 | 3.5 | 3.5 | 3.5 | 3.5 |
| 70 | 2.5 | 1.5 | 1.5 | 1.5 | 1.5 | 2.5 | 2.5 | 2.5 | 2.5 | 2.5 | 2.5 | 2.5 | 2.5 |
| 71 | 9.5 | 6.5 | 6.5 | 9.5 | 8.5 | 6.5 | 8.5 | 9.5 | 9.5 | 9.5 | 9.5 | 9.5 | 9.5 |
| 72 | 2.5 | 1.5 | 2.5 | 2.5 | 2.7 | 1.5 | 1.5 | 2.5 | 2.5 | 2.5 | 2.5 | 2.5 | 2.5 |
| 73 | 5.5 | 4.5 | 4.5 | 4.5 | 4.5 | 3.5 | 4.5 | 4.5 | 4.5 | 4.5 | 5.5 | 5.5 | 5.5 |
| 74 | 7.5 | 3.5 | 4.5 | 4.5 | 4.5 | 3.5 | 4.5 | 5.5 | 5.5 | 5.5 | 5.5 | 6.5 | 6.5 |
| 75 | 5.5 | 3.5 | 3.5 | 3.5 | 4.5 | 4.5 | 4.5 | 4.5 | 4.5 | 4.5 | 4.5 | 4.5 | 4.5 |

*1-1 = Reader #1, reading 1; 1-2 = Reader # 1, reading 2; etc.

PRECISION OF AGING KNOWN AGE BROWN BEAR TEETH*All readers combined*

GRAPH A. MEAN PRECISION OF ALL READINGS OF FOUR AGERS. CEMENTUM AGES FOR 75 KNOWN AGE FIRST PREMOLAR SECTIONS READ 3 TIMES BY EACH AGER.

ACCURACY OF AGING KNOWN AGE BROWN BEAR TEETH
Average deviation from known age by age class



GRAPH B. ACCURACY OF 4 READERS' CEMENTUM AGES FOR 75 KNOWN AGE BROWN BEAR FIRST PREMOLAR SECTIONS.